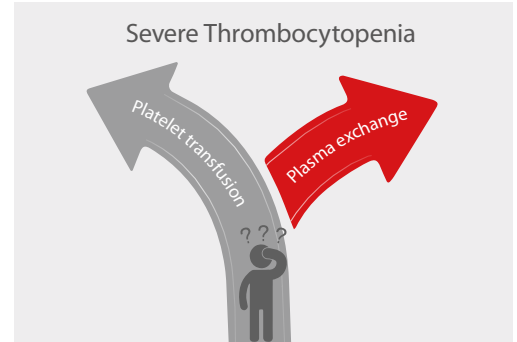


# Is Platelet Transfusion Always Required in Thrombocytopenia?

When the platelet (PLT) count is extremely low, is platelet transfusion really required? Let's analyze the following case, which tells us a different answer.

## Case background

A 49-year-old woman went to the emergency department due to transient cognitive disorder. She had obvious paroxysmal headaches, with vomiting and epigastric pain. Brain CT revealed no abnormalities. The laboratory results revealed anemia and severe thrombocytopenia. What should be expected?

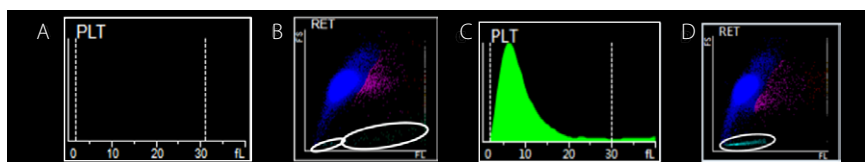


### ► Blood Test

Blood test (Figure 1) showed low RBC count of  $3.07 \times 10^{12}/L$  and low HGB concentration, which indicated anemia. PLT-O count was  $15 \times 10^9/L$  (CDR mode, Mindray BC-6200). Such a low PLT count and abnormal RBC-related parameters caught our attention: Should platelet transfusion be initiated?

Name		XXX					
Gender		Female					
Age		49-year-old					
Items	Results	Reference Range	Unit	Items	Results	Reference Range	Unit
ABO	B			HCT	25.3	35-45	%
Rh	+			MCV	82.6	82.0-100.0	fL
WBC	6.08	3.5-9.5	$10^9/L$	MCH	26.8	27.0-34.0	pg
NEUT%	60.30	40-75	%	MCHC	324	316-354	g/L
LYMPH%	29.50	20-50	%	RDW-CV	14.5	11.0-16.0	%
MONO	8.20	3-10	%	RDW-SD	42.2	35.0-56.0	fL
EO%	1.80	0.4-8.0	%	PLT	15	125-350	$10^9/L$
BASO%	0.20	0.0-1.0	%	MPV	....	6.5-12.0	fL
NEUT#	3.67	1.8-6.3	$10^9/L$	PDW	....	9.0-17.0	%
LYMPH#	1.79	1.1-3.2	$10^9/L$	PCT	....	0.108-0.282	%
MONO#	0.50	0.1-0.6	$10^9/L$	P-LCR	....	19.1-46.6	%
EO#	0.11	0.02-0.52	$10^9/L$	RET#	124.6	22.4-82.9	$10^9/L$
BASO#	0.01	0-0.06	$10^9/L$	RET#	4.6	0.67-1.92	%
RBC	3.07	3.8-5.1	$10^{12}/L$	IRF	14.4	2.4-17.5	%
HGB	82.00	115-150	g/L	LFR	85.6	89.4-99.5	%

Figure 1. Blood test showed low PLT count, RBC count, and increased RET%



The PLT histogram was far from the normal ones. We then checked RET scattergram, in which few PLT dots were observed and RET increased (Figure 2).

Figure 2. Comparison of PLT-I & PLT-O results (A/B: the case; C/D: normal)

These abnormal results triggered the re-exam rule, and then the peripheral blood smear was reviewed (Figure 3). The result demonstrated evidence of intravascular hemolysis, which included schistocytes, a small number of spherocytes, helmet cells, and thrombocytopenia.

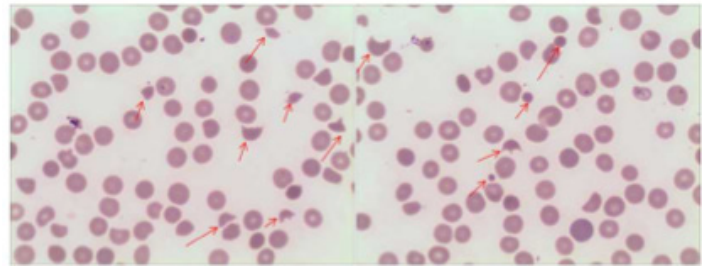


Figure 3. PLT was rarely seen, and schistocytes, small numbers of spherocytes and helmet cells were found. (100x)

► **Bone Marrow Examination**

Erythrocytic cell lines 44%, Granulocytic cell lines 40%, G/E=0.91/1.

Undifferentiated erythroblasts were common in the bone marrow smear, and Howell-Jolly body were found. A total of 257 megakaryocytes were found in the smear, and 50 were differentiated, including 3 megakaryoblasts, 44 promegakaryocytes and 3 naked nucleus megakaryocytes. PLT was rarely seen. Such bone marrow smear showed a megakaryocytic thrombocytopenia, increased function of erythroid differentiation.

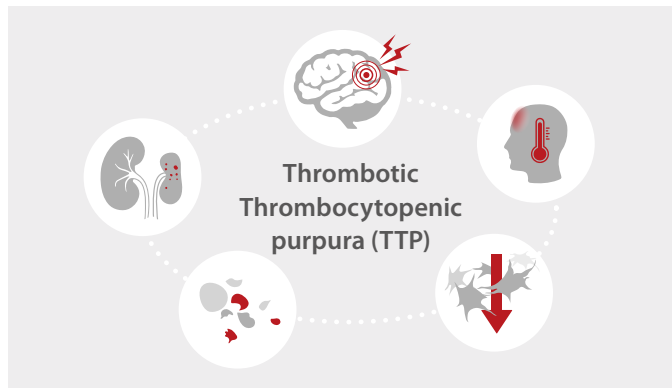
► **Chemistry Test**

In the chemistry test, the result of total bilirubin (TBIL) increased, indirect bilirubin (IBIL) increased, which showed hemolytic disease.

Name	XXX	Unit	Reference Range
Gender	Female		
Age	49		
Items	Resluts	Unit	Reference Range
TBIL	60.50	umol/L	2.0-20.4
DBIL	14.70	umol/L	0.0-6.80
IBIL	45.80	umol/L	3.40-14.00
AST	27.00	U/L	7-40
AST	33.00	U/L	13-35
ALT/AST	1.22		0.23-247
v-Glutamyl transferase	8.00	U/L	7-45
Alkaline Phosphatase	76.00	U/L	40-150
Total Bile Acid	8.00	umol/L	0.00-10.00
Glycocholic Acid	1.39	mg/L	0-2.7
Cholinesterase	8924.00	U/L	4500-13000
Total Protein	65.60	g/L	60.00-95.00
Albumin	39.50	g/L	35.00-55.00
Globulin	26.10	g/L	20.00 40.00
Albumin/Globulin	1.51		1.20-2.40
Glucose	9.15	mmol/L	3.61-6.11
Urine Nitrogen	8.27	mmol/L	1.79-7.14
Creatinine	99.00	umol/L	40-120

Figure 4. Chemistry testing results

Considering the cases with typical symptoms:(1) hemolytic anemia (schistocytes); (2) thrombocytopenia; (3) neurologic symptoms (transient mental disorder), thrombotic thrombocytopenia (TTP) disease is likely. The results and TTP diagnostic suggestion were transferred to doctors immediately. And Further ADAMTS13 testing confirmed TTP. Finally, plasma exchange instead of platelet transfusion was taken.



Five medical signs <sup>[2]</sup>	In this case
Fever	No
Hemolytic Anemia	Yes
Thrombocytopenia	Yes
Transient neurologic symptoms	Yes
Reduced kidney function	No

Figure 5. Clinical symptoms of TTP disease

### Conclusion

If the PLT level is lower than the decision-making threshold, experienced doctors will immediately recheck whether the specimen is qualified, the histogram and scattergram are normal or not, and any other abnormal cell counting results or significant flag messages, etc. Further confirmation will be carried out by blood smear examination under the microscope. Finally, after considering the patient's symptoms and medical history information, the laboratory can report the results and provide possible diagnosis.

Mindray's automatic 8x PLT-O counting (SF Cube technology) provides accurate and stable counting for thrombocytopenia samples. Together with high quality blood smear from SC-120 Auto Slide Maker, Mindray hematology solutions support efficient management of thrombocytopenia. PLT-O is available in Mindray BC-6000 Series Auto Hematology Analyzers, and the CAL 8000/6000 Cellular Analysis Lines.

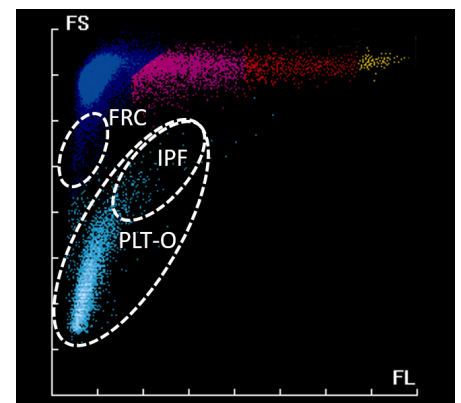


Figure 6. PLT-O scattergram

### Extension: Why is platelet transfusion not recommended in thrombotic thrombocytopenia?

Common causes of thrombocytopenia include decreased production in bone marrow, increased destruction in peripheral blood, and medication induced<sup>[1]</sup>.

Thrombotic thrombocytopenia, including TTP in this case, is a kind of disease caused by increased PLT destruction. Because of von Willebrand factor (VWF) cleavage protease (ADAMTS13) deficiency, VWF cannot be cut off normally, and ultra-large VWF (ULVWF) accumulate, resulting in abnormal PLT aggregation, microthrombosis and fragmented RBC<sup>[2]</sup>. Under such condition, platelet transfusion may accelerate thrombosis, leading to worsening symptoms<sup>[3]</sup>. So for thrombotic thrombocytopenia, the main treatment should be plasma exchange.

### Acknowledgement

We would like to extend our thanks to Dr. Xiao Zuomiao, Dr. Chen Xianchun, Dr. Xiao Dejun and Dr. Luo Shi from Ganzhou People's Hospital, China, for providing the case information.

### References:

[1] What Is Thrombocytopenia? - NHLBI, NIH". www.nhlbi.nih.gov. Retrieved 2015-05-01.  
 [2] Tsai, Han-Mou(2010). "Pathophysiology of thrombotic thrombocytopenic purpura." International journal of hematology vol. 91,1: 1-19. doi:10.1007/s12185-009-0476-1.  
 [3] Joly, BS; Coppo, P; Veyradier, A (2017). "Thrombotic thrombocytopenic purpura." Blood. 129 (21): 2836–2846. doi:10.1182/blood-2016-10-709857.

# healthcare within reach

## MINDRAY SOCIAL MEDIA CHANNELS

LinkedIn



[www.mindray.com](http://www.mindray.com)

P/N: ENG-HemaBook-TTP-210285X4P-20201120

©2020 Shenzhen Mindray Bio-Medical Electronics Co.,Ltd. All rights reserved.

**mindray**  
healthcare within reach