

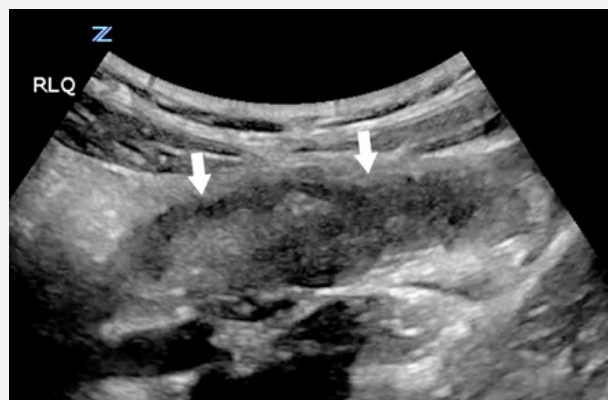# Gangrenous Appendicitis in a Pediatric Patient.

## Case Report

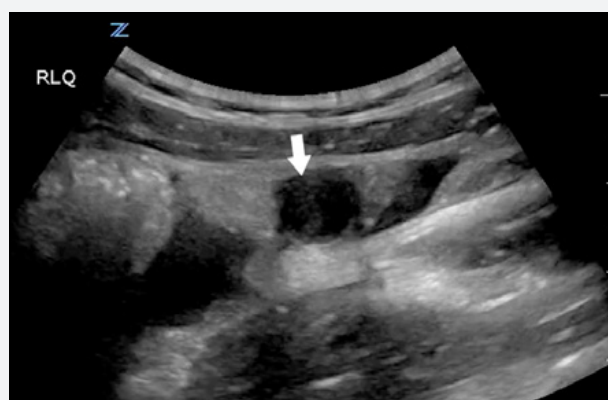
### Full Story

A 7 year old girl presented to the Emergency Department (ED) with nondescript lower abdominal pain and nausea of two days duration. On physical examination she was tender in both lower quadrants. She was afebrile and her white count was within normal limits. A preliminary ultrasound examination using a traditional beamforming imaging platform failed to visualize the appendix or any lower abdominal pathology. Still suspicious of occult pathology, the attending pediatric ED physician requested a second ultrasound opinion, which was performed by an emergency medicine ultrasound specialist using the ZONARE Z.One PRO. Powered by proprietary ZONE Sonography™ Technology (ZST™) which maintains unparalleled spatial and contrast resolution at all imaging depths, the second ultrasound study clearly demonstrated acute inflammatory pathology in the right lower quadrant.

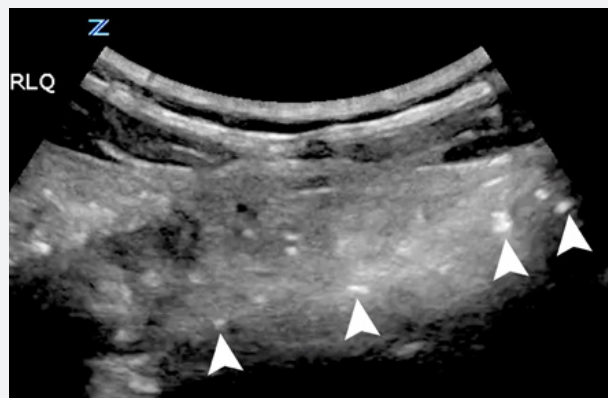
Sagittal section through the lower abdomen revealed a large, dilated, thick-walled appendix filled with heterogenous fluid. (Figure 1) Small punctate echogenic foci were noted within representing microbubbles that are common in emphysematous inflammatory states. (Figure 2) Additional sonographic findings included a large calculus within the appendiceal lumen (appendicolith) and a small amount of complex free fluid in the periappendiceal space. (Figures 3 and 4) All of these sonographic findings were consistent with acute ruptured appendicitis and the patient was urgently transported to the surgical suite. Operative examination confirmed the diagnosis of gangrenous appendicitis with microperforations. The diseased appendix was removed and the postoperative course was unremarkable. Had the child been released from the ED based on the results of the initial ultrasound examination, catastrophic sequelae surely would have ensued.



**Figure 1a.** Large inflamed appendix filled with heterogeneous fluid (arrows).

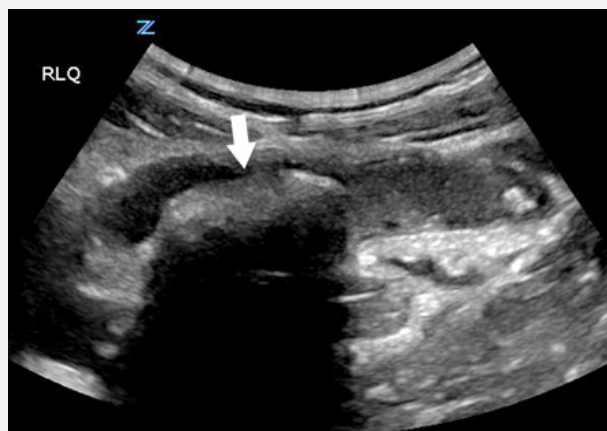

**Figure 1b.** Transverse section through the same area.

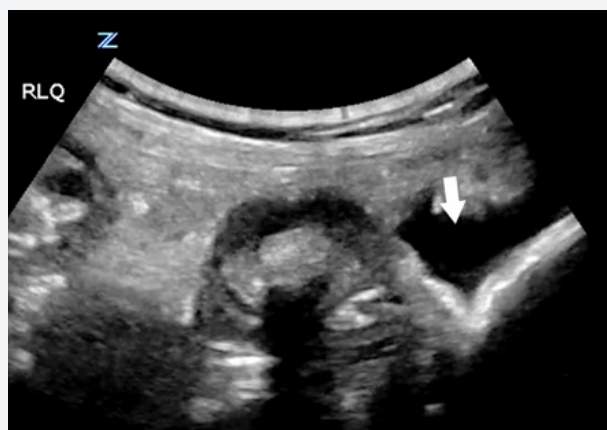


**Figure 2.** Multiple punctate echogenic foci within the appendix consistent with inflammatory microbubbles.

Successful and accurate bedside ultrasound imaging in emergency medicine requires uncompromised image quality, portability, and ease of use. Unfortunately, most hardware-based beamforming ultrasound systems have a tradeoff between image quality and portability, which can have serious diagnostic consequences. ZONE Sonography Technology, however, is the first software-based image formation process to guarantee unparalleled focus and clarity across the entire image, supporting the most accurate diagnosis possible. The Z.One PRO, like all of ZONARE's products, combines premium imaging with both portability and ease of use, critical components in bedside ultrasound examinations.



**Figure 3.** Large calcified appendicolith (arrow) in a large, inflamed appendix.



**Figure 4.** Free fluid (arrow) adjacent to the appendix.



## Author

Gerardo Chiricolo, MD, FACEP  
Past Chair, ACEP Ultrasound Section  
Chair, Division of Clinical Ultrasound  
Director, Division of Emergency Ultrasound  
Director, Emergency Ultrasound Fellowship  
NY Methodist Hospital



*Celebrating 10 Years of Innovation*

ZONARE Medical Systems, Inc  
420 N. Bernardo Ave  
Mountain View, CA 94043-5209

Phone: (650) 230-2800  
Email: [info@zonare.com](mailto:info@zonare.com)  
[www.zonare.com](http://www.zonare.com)