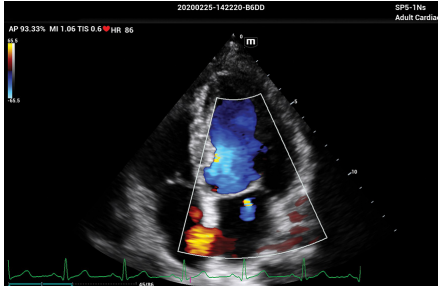


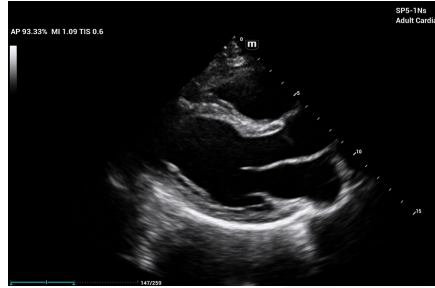
ME8 Ultrasound System

Clinical Images

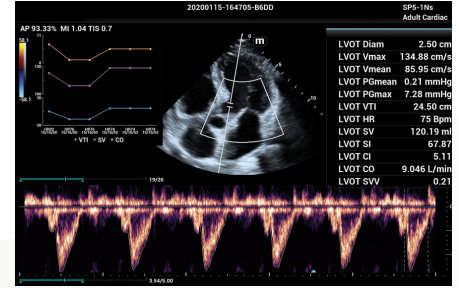
Phased



Apical 4 Chamber

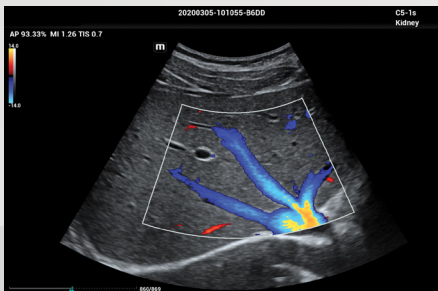


Parasternal Long Axis

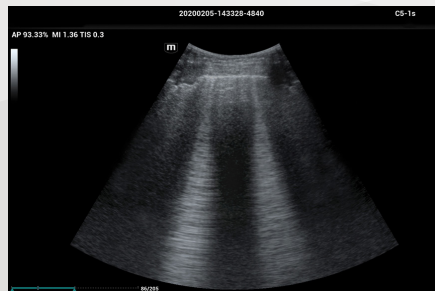

Apical 5 Chamber

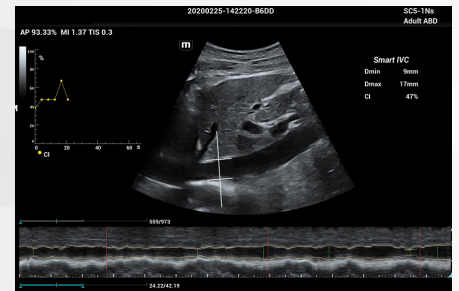
Curved



Liver

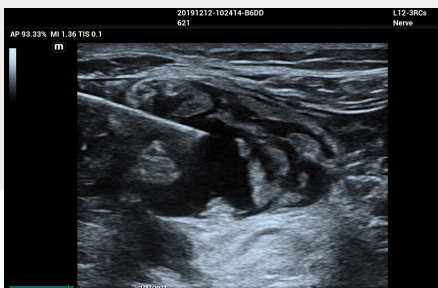

Lung

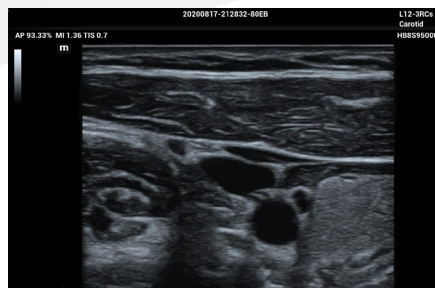

Inferior Vena Cava

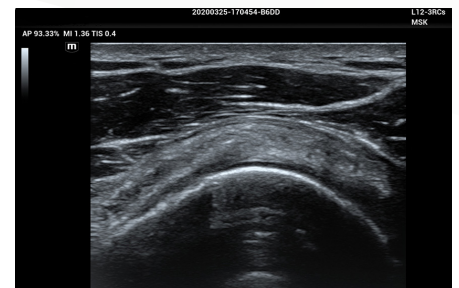Linear



Brachial Plexus



Jugular Vein



Rotator Cuff