



White Paper

TRUS, Elastography, and US Guided Prostate Biopsy

Pavlos S. Zoumpoulis MD, Ph.D.

mindray
healthcare within reach

CONTENT

1.Introduction 02-03

1.1 Aim 02

1.2 Prostate Anatomy 02

1.3 Prostate Cancer Topography 02-03

2.Ultrasound Prostate Applications (US Technology) 03-13

2.1 TRUS 03-07 2.3 Prostate Biopsy 10-13

2.1.1 TRUS Technique	04	2.3.1 TRUS Guided Biopsy	10
2.1.2 Probe Preparation & Patient Position	04	2.3.2 Equipment	10
2.1.3 TRUS Examination	04-05	2.3.3 Patient Preparation	10-11
2.1.4 TRUS semiology	05-06	2.3.4 Probe preparation	11
2.1.5 TRUS Limitations	05-06	2.3.5 TRUS/STE examination	11
2.1.6 Color Doppler Examination and Semiology	06-07	2.3.6 Biopsy	11-12

2.2 Elastography 07-10

2.2.1 Elastography Technique	08-09	2.3.7 Complications	12
2.2.2 Elastography semiology	09	2.3.8 MpMRI/TRUS Fusion Guided Biopsy	12-13
2.2.3 Elastography Limitations	09-10	2.3.9 Transperineal Biopsy	13
		2.3.10 Prostate Cancer Histology	13

3.Resona 7 TRUS Examination & Prostate Biopsy Step-by-Step 14

1.Patient preparation	14
2.Probe preparation	14
3.TRUS examination	14
4.Elastography	14
5.TRUS guided biopsy	14
6.Avoiding hemorrhage	14
7.Avoiding vagotonia and trauma	14

4.Interesting Cases 15-22

Interesting Case 1 15-16

Interesting Case 2 17-18

Interesting Case 3 19-20

Interesting Case 4 21-22

5.References 23-24

1. Introduction

1.1 Aim

Aim of this White Paper is to provide clinicians with a guide on TRUS examinations and US guided Prostate biopsies, using the Resona 7 system and the V11-3HU and ELC13-4U probes.

Proper training is essential in both TRUS examinations and, especially, in US guided prostate biopsies, which are associated with potential important complications. This document does not replace the Guidelines by WFUMB and EFSUMB [1-4], but serves as a guide for Resona 7 US system users.

1.2 Prostate Anatomy

The Prostate gland is located in front of the rectum and below the bladder and consists of the base, the apex, as well as the anterior, posterior and two lateral surfaces. The Prostate is divided into anatomical lobes, namely the inferoposterior, inferolateral, superomedial, and anteromedial lobes.

The more clinically important prostate division, however, breaks the Prostate down in the central, peripheral and transitional zones. The Transitional Zone (TZ), which surrounds the urethra, is small in young adults, but grows throughout life. Benign Prostatic Hyperplasia (BPH) develops in the TZ and is responsible for gland enlargement that occurs with aging, causing urinary problems. The central zone is located around the ejaculatory ducts and the TZ, surrounds the urethra, but shrinks in most adult cases, due to TZ hypertrophy. The Peripheral Zone (PZ) constitutes the main body of the Prostate and is located in the posterior part of the gland. Both acute and chronic inflammation, as well as Prostate Cancer (PrCa) often occur in the PZ. Finally, the fibromuscular stroma is located in the anterior part of the gland [5].

In order to simplify and standardize terminology and content of radiology reports for the Prostate, the Prostate Imaging Reporting and Data System – PI-RADSv2 system was developed. This system defines a five-grade scale for Prostate Tumor Malignancy Risk and introduces a unified Prostate anatomical segmentation scheme as shown in Figure 1.

A perfect understanding of Prostate anatomy is crucial for diagnosing and locating PrCa (Figure 1).

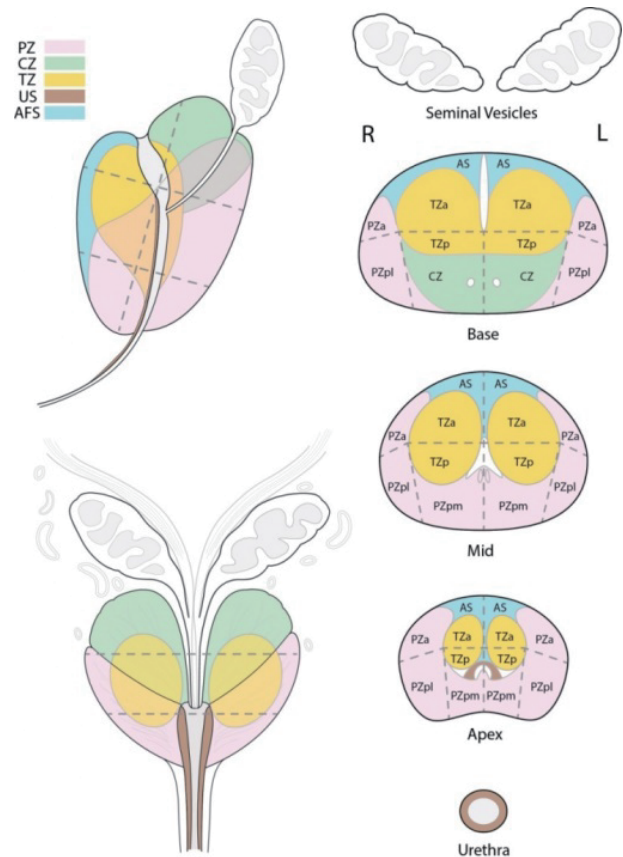


Figure 1. PI-RADS anatomic scheme, showing different Prostate segments

1.3 Prostate Cancer Topography

About 75-80% of PrCas are located in the PZ [6], which is located near the rectum. This position allows a transrectal probe to approach the PZ and use high (7-15kHz) US frequencies to provide a reliable, precise,

and high-resolution US examination, visualizing even small (2-3mm diameter) prostatic neoplasms.

Approximately 20-25% of PrCas are located in the Transitional Zone (TZ) [6], where the capacity of TRUS is significantly weaker. The distance between the transrectal probe and the TZ is larger, weakening the US beam signal. TRUS imaging capacity in the TZ is further jeopardized by the many acoustical obstacles, such as calcifications and hyper/hypo echoic lesions, which are common findings of prostatic infections and hyperplasia nodules. These TZ limitations mean that lesions located in the anterior segments of the TZ and in the anterior neurovascular stroma are not visualized in TRUS and are, therefore, practically impossible to target through TRUS guidance alone.

Special attention should be paid on the visualization of the anterior segments of the PZ, mainly in the middle of the gland. These anterior segments are usually located 4-6 cm from the transrectal probe, which makes their visualization challenging. The examiner should be aware of the challenges posed by the lesions located in these segments, which usually make reliable visualization of the anterior PZ impossible.

2. Ultrasound Prostate Applications (US Technology)

2.1 TRUS

Modern high frequency TRUS probes offer precise prostate visualization. Even though multiple types of phased array and mechanical probes are commercially available, the main types of probes that are useful in TRUS examination and in TRUS-guided Prostate biopsies are Endfire and Bi-Plane probes. Each

transducer type is characterized by specific capabilities and limitations.

Endfire probes are equipped with a convex transducer and offer adequate visualization for both the PZ and the posterior segments of the TZ, thus allowing effectively locating and targeting tumors in these areas (Figure 2).

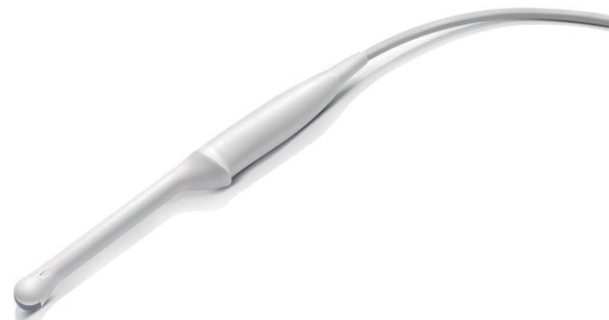

Figure 2. The V11-3HU transducer

Biplane probes, on the other hand, are equipped with both a convex and a linear transducer, which send the US beam in vertical directions. There are some limitations posed by all Bi-plane probes' architecture. Although the apical segments of the PZ are ideally accessible, the segments of the base are challenging to visualize. The micro-convex part of biplane probes does not usually have the flexibility of proper positioning in the rectum to access all segments of the PZ. The high-frequency linear probe may be positioned in direct contact with the rectal wall and the PZ, thus allowing a high-quality US visualization of the median segments of the PZ. The linear probe, however, is not applicable for lateral PZ segments or TZ visualization, due to its high frequency not being suitable for areas situated more than 4 cm from the probe. The main advantage of the ELC13-4U probe is its capacity to provide the examiner with a bi-planar view combining transversal and sagittal planes of a certain area. Biplane transrectal transducers, therefore, provide additional useful clinical information and a better understanding of the specific position and morphology of a lesion (Figure 3).

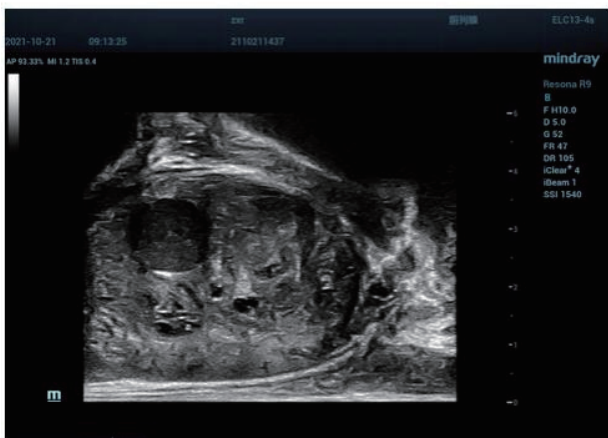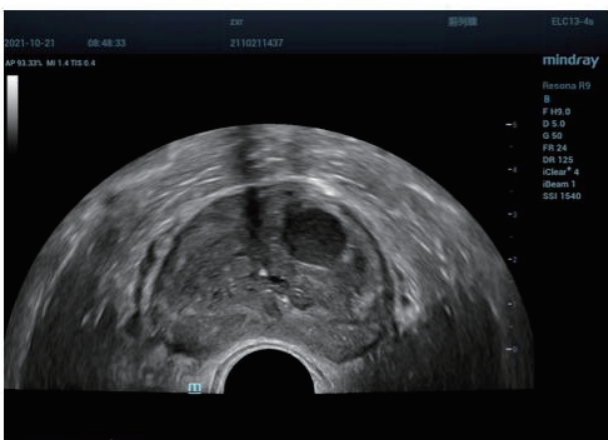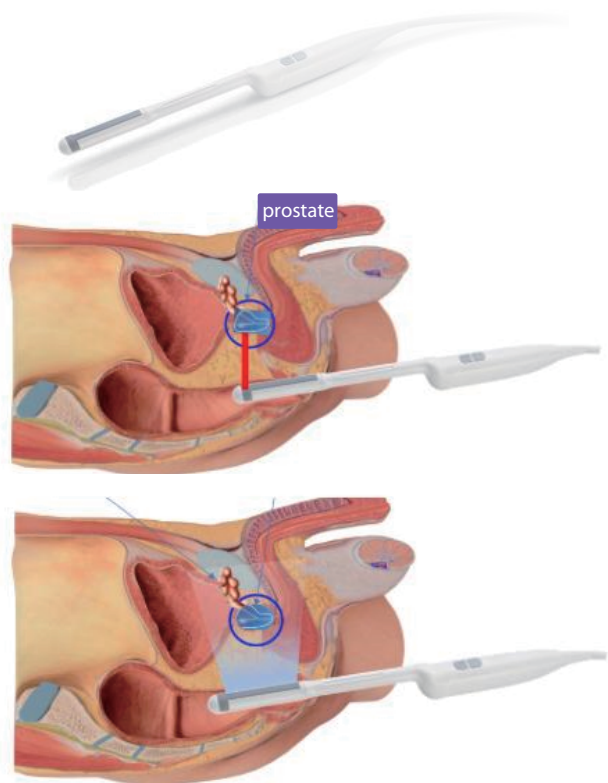


Figure 3. The ELC13-4U transducer has the capacity to combine transversal and sagittal planes of a certain area

It could be argued that the Endfire and Biplane probes are complementary. End-fire probes are generally reliable in visualizing and targeting most PZ tumors, while biplane probes provide excellent visualization of the Prostate's apex and provide the examiner with additional clinical information. Mainly Endfire transducers, however, should be used in transrectal biopsies, while biplane probes are suitable for trans-perineal biopsies.

This White Paper mainly focuses on the use of the V11-3HU transducer because of its flexibility and capacity to reliably visualize PZ lesions, as well as proximal TZ lesions.

2.1.1 TRUS Technique

Due to the operator dependent nature of US examinations, extensive training and appropriate technique are essential. This need is amplified in TRUS examinations, where the challenging Prostate anatomy often leads to difficulty in finding the appropriate acoustical windows and visualizing all PZ and TZ segments.

2.1.2 Probe Preparation & Patient Position

The TRUS examination technique starts with the appropriate preparation of the probe and the placement a protective cover around it (two protective covers are needed for a Prostate biopsy). A small quantity of US gel should be placed both between the cover and the probe and on the cover to avoid air residue and ensure perfect probe-transducer acoustical contact. The patient should lie in his left side with his knees bent.

2.1.3 TRUS Examination

TRUS examinations should be mainly carried out using the V11-3HU transducer. The ELC13-4U probe may be used to visualize apical and proximal PZ lesions.

Some PZ Tumors are better visualized through longitudinal sections (i.e., Tumors located near the middle line, in segment PZpm), while other tumors are better visualized through transverse sections (i.e., Lateral tumors located in the segment PZpm). Special attention should be paid to tumors located in the PZ anterior segments (segment PZa), since these lesions are often more distant (3-5 cm) from the probe (Figure 1).

Examining the entire prostatic parenchyma through TRUS, therefore, requires methodical examination protocol and precise probe handling. As a general rule, the examiner should aim to detect PZ lesions and reliably visualize them by placing the edge of the probe in acoustical contact with the lesion and as close to the lesion as possible (Figure 4).

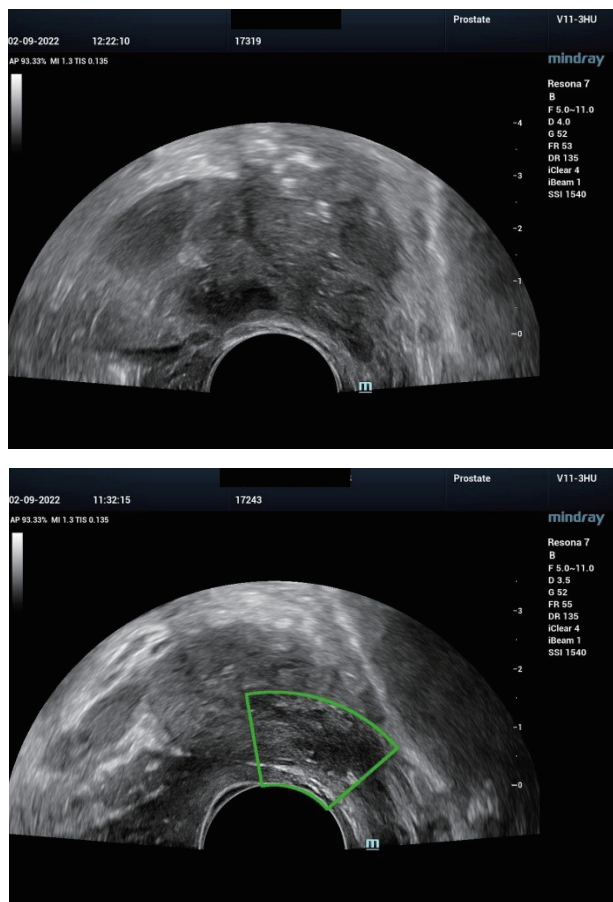


Figure 4. Hypoechoic PZ lesion (V11-3HU probe). Up: transverse section. Down: Longitudinal section (HD Scope)

The examiner should start the examination by performing transverse prostate sections in the right PZ from the apex through the base of the gland and then repeat the process for the left PZ. The examiner should, subsequently, turn the probe 90° and scan the segments of the PZ in longitudinal sections, starting from the median line and moving towards the left and then the right side of the gland. Doing so the examiner ensures the complete and reliable US visualization of the PZ by performing both transverse and longitudinal scans for every segment.

After completing the PZ B-Mode examination, the examiner may then focus on the TZ posterior segments, scanning from the apex through the base for both left and right TZ sides. Every detected lesion, in both PZ and TZ, should be scanned in both transverse and longitudinal sections to reliably visualize its margins.

During the constant adjustments of the probe, required to visualize all prostatic segments, the examiner should assure perfect acoustical contact between probe and rectal wall. Light probe pressure towards the prostate is required to avoid air residue between probe and rectal mucosa.

2.1.4 TRUS semiology

Most PrCas are typically located in the PZ and initially appear as hypoechoic lesions in contact with the Prostate's capsule. As PrCas grow in size, they typically attain an ovoid shape, extend in contact with the capsule and, in a later stage, may expand to the TZ and invade the periprostatic fat (Figure 5).

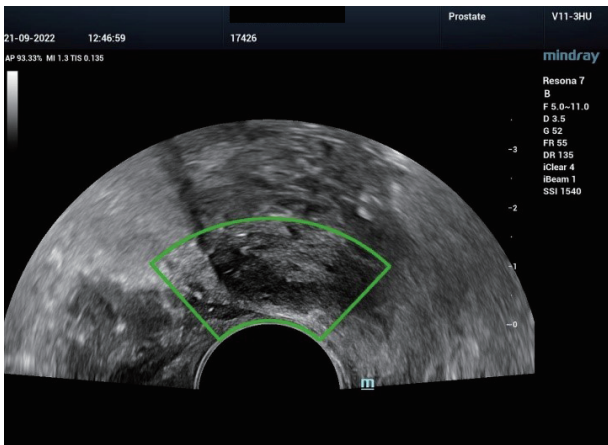


Figure 5. Longitudinal PZ section (V11-3HU probe). Hypo-echoic tumor from the apex through the base of the gland, invading the capsule (HD Scope).

Even though PrCas are mostly hypoechoic, they may also be isoechoic (approximately 25%), with no clear echogenicity distinction from the normal PZ prostatic parenchyma [7]. In such cases, and only if the tumor has invaded the capsule and/or the TZ, the mass effect (lobulation) is the only B-Mode finding pointing towards malignancy (Figure 6).

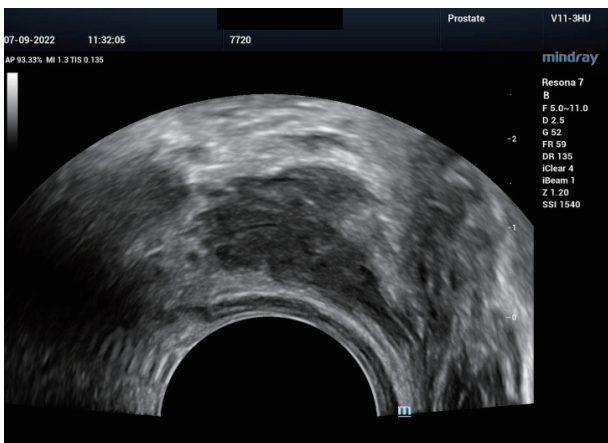


Figure 6. Longitudinal section (V11-3Hu probe): hypo/iso-echoic tumor from the apex through the base, invading the capsule (lobulations)

On the other hand, not every PZ hypoechoic lesion is a PrCa. On the contrary, infections and hyperplastic PZ nodules often appear as hypoechoic lesions in B-Mode, thus mimicking neoplasms. This is the main reason why TRUS alone is characterized by poor sensitivity and specificity values for ambiguous hypo-echoic PZ lesions [8].

2.1.5 TRUS Limitations

The most important limitation of TRUS examinations is the limited capacity to reliably visualize the Prostate's TZ. Adenomatous prostatic hyperplasia TZ nodules, and the often-co-existing infectious nodules, may perplex the examiner or act as acoustic obstacles. Although only 20-25% of PrCas evolve in the TZ [6], typical hypoechoic TZ neoplasms are almost impossible to recognize and may be concealed between many other hypoechoic lesions in the hyperplastic and chronically infectious TZ. In contrary to the B-Mode capacity to visualize and differentiate PZ lesions, differential echogenicity should not be viewed as a criterion for detecting PrCas in the TZ.

Even though TRUS has the capacity to assess PrCas in the Prostate it is operator dependent. Specifically, TRUS diagnostic accuracy in evaluating extracapsular extension ranges from 37% to 85%, depending on the examiner's experience in performing and interpreting the examination [8].

2.1.6 Color Doppler Examination and Semiology

The conventional Color Doppler examination is often time consuming and may not offer specific diagnostic criteria based on the hemodynamic behavior of the lesions. Only a small number of tumors present typical hyper-vascular pattern. Typical neo-vessels and typical

vascularization appear only in very large tumors. Technology advances, however, may lead to the emergence of new Color Doppler PrCa semiology.

Mindray's Ultra-micro-angiography (UMA) is a novel Doppler technique which enhances the identification rate of vessels. UMA is characterized by superior sensitivity for low-velocity blood flow than the traditional Color Doppler, due to improved wall filters, resulting in capacity to visualize microvascular morphologies [9]. UMA may, therefore, visualize the typical neoplasm hyper vascular pattern, significantly contributing in PrCa differential diagnosis (Figure 7).

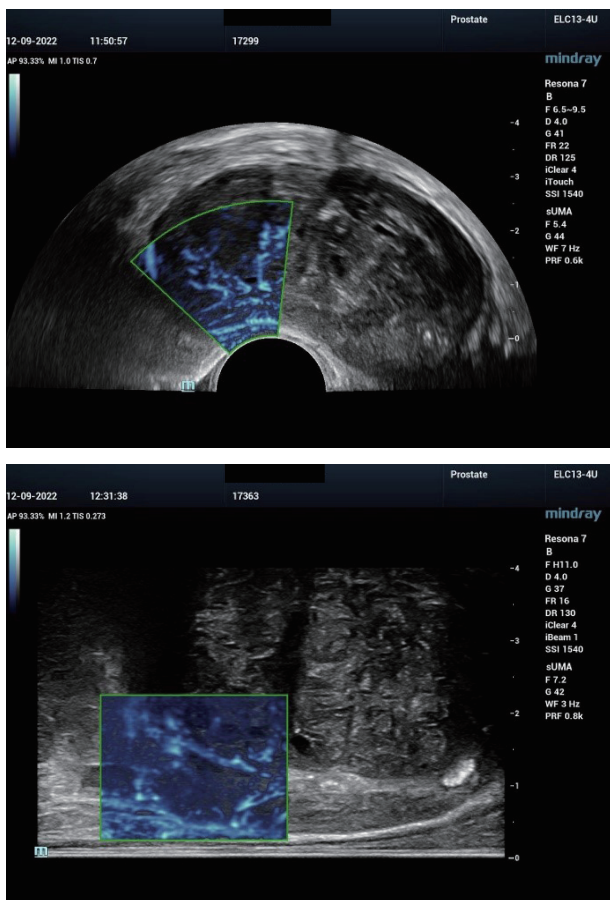


Figure 7. UMA feature application (ELC13-4U Probe). Up: Transverse section, normal PZ vascularization, vessels running parallel to the capsule. Down: Longitudinal section, neo-vessels in the periphery of a PrCa

2.2 Elastography

Changes in tissue stiffness are related to various diseases such as development of carcinoma and fibrosis in the liver. Elastography is a useful quantitative tool, used in various clinical applications for measuring tissue stiffness. There are various US-Elastography variants based on the same physics principles but on different technologies and usage guidelines, such as Strain or Real Time Elastography (RTE), Vibration-Controlled Transient Elastography (VCTE), Acoustic Radiation Force Impulse Elastography (ARFI), Shear Wave Elastography (SWE) and Sound Touch Elastography (STE). Strain Elastography and VCTE employ user-dependent external mechanical force to generate tissue deformation and extract tissue stiffness differences. ARFI, SWE and STE employ internal Acoustic Radiation Force Pulse excitation to generate tissue deformation in various depths and measure its differences [10-14]. Specifically, SWE and STE technologies are similar and based on the same physics principles, meaning that they share comparable guidelines and examination protocol. This White Paper focuses on the use of Strain and STE Elastography developed by Mindray and offered through the Resona 7 US system.

Both Strain and SWE/STE work reliably in Prostate applications and are often complementary. Specifically, Strain Elastography is usually more reliable in proximal PZ lesions. However, Elastographic assessment of the PZ distal segments is often impossible through Strain Elastography. Since Strain requires rhythmical pulses on the prostate to produce strain color mapping, it greatly depends on probe handling.

SWE/STE, on the other hand, is less operator-dependent and can reliably assess the stiffness of the entire PZ. SWE/STE requires stability of both the probe and the Prostate to produce reliable color coding with no artefacts.

2.2.1 Elastography Technique

A reliable elastographic assessment should always be based on a perfect US image. The examiner should, after detecting hypo-echoic PZ lesions through TRUS, assess their stiffness. The transducer should be placed as close as possible to the targeted lesion. It is important that the US beam is perpendicular to the lesion's most proximal margins. When applying Elastography, the Elastography ROI should include the targeted lesion and the surrounding PZ normal parenchyma, in order to be able to compare their stiffness.

The Elastographic examination, for both SWE/STE and Strain Elastography, should start by visualizing the PZ-TZ differentiation (Figure 8).

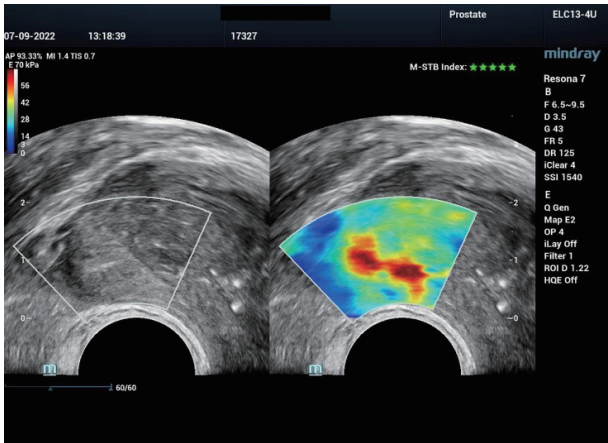


Figure 8. Normal PZ-TZ differentiation (ELC13-4U probe). The PZ appears softer (blue) than the TZ (red).

As the TZ is always stiffer than the PZ, this differentiation assures the examiner that the Elastographic color box is reliable and may help in adjusting the color map scale range appropriately in order to visualize this differentiation. This action, however, should be exercised with caution as choosing a range larger than the stiffness differences would lead to a completely homogeneous color box that provides no visual information on stiffness differences.

Even though cut-off values regarding the PZ parenchyma-tumor differentiation are present in the litera-

ture [1], the real value of Elastography in the Prostate stems from its capacity to indicate that a suspicious hypo-echoic lesion in the PZ is stiffer, or as stiff as the surrounding PZ parenchyma. Stiffer lesions should be targeted during Prostate biopsies [1].

a. STE

Immobility of both the rectal probe and the Prostate are important preconditions for applying STE. After visualizing the PZ-TZ differentiation and adjusting the color map scale range, the examiner should assess the stiffness of detected hypo-echoic lesions by, firstly, placing the transducer as described above. After pressing the STE button, the examiner should wait for the STE color box to stabilize and assess the difference in stiffness between the lesion and the surrounding parenchyma.

To guarantee measurement reliability the Resona 7 system introduces two reliability indexes. The motion stability index aids the examiner in ensuring the immobility of transducer and Prostate parenchyma. 4 or 5 green stars indicate a high stability of consecutive frames and, therefore, high reliability (Figure 9).

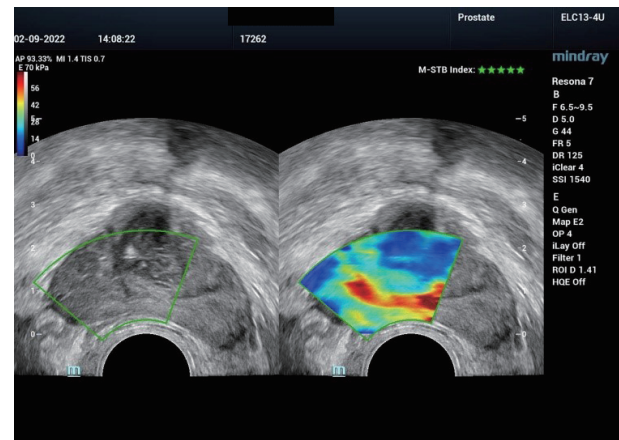


Figure 9. The 5-star stability index ensures immobility of transducer and Prostate parenchyma (ELC-4U probe). Normal PZ-TZ differentiation. The PZ appears softer (green/yellow) than the TZ (red). The urethra and the frontal neurovascular space in the middle of the gland appear softer (blue).

b. Strain Elastography

After appropriate probe placement, the examiner should perform small periodical compressions using the transducer, to generate a continuous series of images. It should be noted that excessive pressure could create artefacts and unreliable stiffness measurements and mapping. For this reason, the Resona 7 system provides an index bar to determine the appropriate compression. When appropriate probe/rectal wall contact is maintained the index bar is filled with continuous green waves that reach at least the middle and extend to the top. This assures that the manual compression is adequate.

After the Strain Elastography color box is available, the examiner should assess the difference in stiffness between the lesion and the surrounding parenchyma.

2.2.2 Elastography semiology

A typical PZ PrCa, being stiffer than surrounding prostatic parenchyma, appears red in the STE color box, in contrast with the softer PZ parenchyma that appears blue (Figure 10).

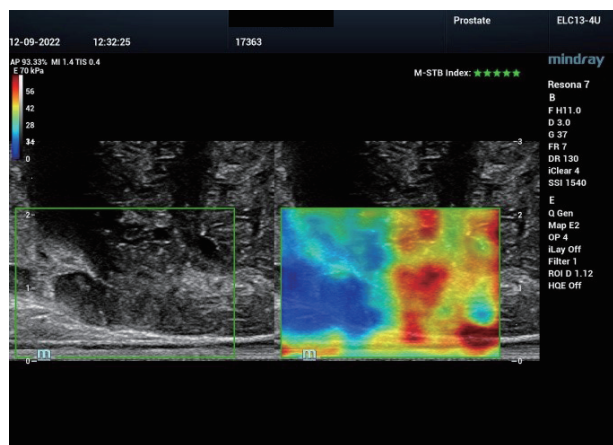


Figure 10. A PZ PrCa. The normal PZ appears soft (blue). Although the tumor is not clearly visible in B-Mode (iso-echoic), it appears stiff (red and yellow) in Elastography.

Very stiff lesions may fully reflect the Shear Waves, thus creating an artefact which appears as a dark blue area in the STE color box. Despite being an artefact, this phenomenon may be very useful in TRUS examinations and in guiding Prostate biopsies. It contributes in delineating very stiff tumors and may, in rare PrCa cases, differentiate a malignant tumor from less stiff adenomatous nodules (Figure 11). Suspicious PZ lesions, on the other hand, that do not present increased stiffness or the above artefact are less likely to be malignant than suspicious lesions that appear stiffer more suspicious lesions rather than the lesions that appear soft in Elastography.

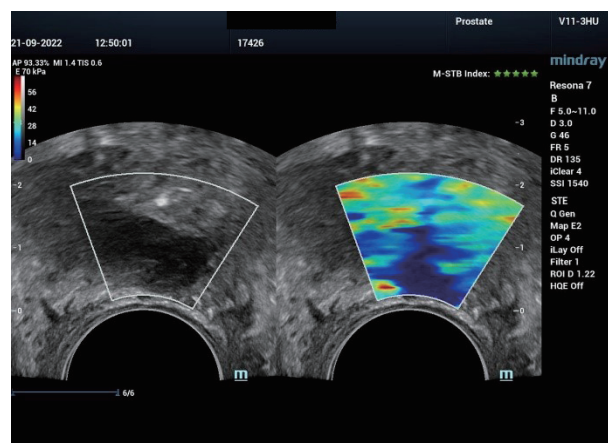


Figure 11. Typical PZ hypo-echoic lesion (V11-3HU probe) that presents the dark blue area artefact.

2.2.3 Elastography Limitations

The main limitation of Elastography in Prostate applications is its limited capacity in the TZ. Adenomatous hyperplasia TZ nodules are stiffer than the normal TZ parenchyma and appear stiff in Elastography. It is, therefore, almost impossible to differentiate a stiff TZ PrCa from stiff infection or a hyperplasia nodule. Furthermore, calcifications (which

are common in the TZ) act as acoustic obstacles, further limiting Elastographic imaging in the TZ. Elastography may play a role in the TZ only in rare cases, in which a lesion is located in the TZ posterior segments (TZp) and in close proximity to the transducer (<2,5cm). In such cases, a reliable SW color box may be produced, and the lesion's stiffness can be compared with the PZ normal parenchyma. SWE, despite its usefulness in providing additional diagnostic information, is characterized by variable diagnostic performance [15-17].

2.3 Prostate Biopsy

The Reference Standard for PrCa diagnosis and aggressiveness estimation is Prostate histology, provided by Prostate Biopsy. Prostate Biopsy is usually performed using Ultrasound and/or MRI guidance. There are mainly two different approaches for performing Prostate Biopsies, each with its strengths and limitations: Transrectal and Transperineal Biopsy. This White Paper discusses both approaches, but focuses mainly in TRUS-guided biopsies.

2.3.1 TRUS Guided Biopsy

The transrectal approach is often preferred by physicians due to its convenience, short learning curve and low cost. Moreover, the procedure does not usually require anesthesiology specialized staff and equipment, since it may be performed under local anesthesia [18]. The procedure involves a needle passing through the rectal wall and, therefore, a risk of Prostate inoculation by rectal bacteria. To prevent infections, therefore, an enema and prophylactic antibiotics are administered prior to the Biopsy [18]. Even though progress in US and MRI-targeted biopsy has partly resolved inaccuracy and high false negative rate issues, transrectal biopsies are still associated with complications, such as rectal bleeding, fever, sepsis,

hematuria and acute urinary retention [19].

A detailed note describing the procedure, its preparation and potential complications should be shared with both the patient and his referring clinician. The patient should also sign an informed consent form before undergoing a Prostate Biopsy.

2.3.2 Equipment

The TRUS-guided Prostate biopsy procedure requires an US system, a transrectal transducer and a biopsy gun with a compatible needle.

A Biopsy gun is an instrument that projects a thin needle into suspect prostate gland areas, and removes small sections of tissue to be later used for analysis. Multiple categories of Prostate Biopsy guns are commercially available, including automatic, semi-automatic, disposable and multi-use guns. Some commercially available Biopsy guns allow the user to specify the extracted specimen length.

The choice of the biopsy gun and needle is up to the examiner. The multipurpose gun holds multiple advantages over automatic guns, since it may be re-used. Moreover, multi-use guns are compatible with dividable needles that allow US-guided local anesthesia. This White Paper focuses on performing TRUS-guided Prostate biopsies using a multi-use gun and a dividable needle.

2.3.3 Patient Preparation

Actions required before the patient arrives in medical facility

Any anti-coagulation treatment (i.e., acetylsalicylic acid) should be ceased for at least 10 days before the Prostate biopsy takes place.

An antibiotic daily treatment (quinolone 1000mg & metronidazole 500mg) should be administered to the patient, starting from the day before the Prostate

biopsy takes place and for 4 days.

A self-induced cleansing enema should be performed by the patient 1-2 hours before the Prostate biopsy takes place.

Actions required in medical facility before the Prostate biopsy takes place

Local antiseptic (i.e., povidone-iodine) should be placed in the rectum before starting the examination. This limits the possibility of microbe insertion in the prostate during the multiple needle punctures.

Local anesthesia, through xylocaine gel placement in the rectum should be used in patients with specific anatomic conditions, such as anal stenosis or stretch marks.

Although local anesthesia is usually adequate, sedation is useful, mainly in patient cases that have undergone a previous painful biopsy. It is induced by intravenous sedative drug administration and requires the presence of an anesthesiologist. It lengthens the examination time, has rare complications (i.e., aspiration, intraoperative awareness, postoperative pulmonary complications) and is required only in special cases, due to the effectiveness of US guided local anesthesia [20].

Local US-guided anesthesia, using 8-10 ml of xylocaine, assures a painless procedure and, therefore, patient collaboration. If the local anesthesia is appropriately performed, the patient should only feel slight stinging in the urethra.

Using a dividable needle, the examiner may use the needle canula to perform US-guided local anesthesia. The anesthetic drug (xylocaine) should be injected under US guidance, taking into account the neural anatomy of the gland. Two anesthetic injections should be performed on the left and right of the media line, at the base of the prostate. Since the edge of the needle is clearly visible through B-Mode, the

examiner can be very precise on the anesthetic injection placement. Air inclusion both from the syringe containing the anesthetic and the needle must be avoided to avoid B-Mode image disturbance.

2.3.4 Probe preparation

Probe preparation for transrectal Prostate biopsies involves covering the transducer with two protective covers. The first cover is placed between the probe and needle guide, while the second cover is placed over the guide. US gel should be placed both between the first cover and the probe and between the two covers, to avoid air inclusion. This is vital as even a small quantity of air in front of the probe's acoustical surface could cause important image quality degradation, producing artificial US image findings, such as artefacts and shadows. A small quantity of antiseptic gel should be placed on the second cover before the probe is inserted in the rectum, to limit the possibility of infectious complications.

2.3.5 TRUS/STE examination

Before the biopsy is performed, a holistic B-Mode and STE examination of the Prostate should take place, as described above. Specifically, longitudinal, and transverse sections of both the PZ and TZ should be carried out to visualize hypoechoic lesions in the Prostate. Subsequently, an Elastographic evaluation of the detected hypoechoic lesions should take place, starting from the PZ.

2.3.6 Biopsy

After the suspicious lesions have been detected tissue should be extracted from every PZ lesion to prove malignancy or benignity (typically only one PZ lesion is visible). The needle should be US-guided towards a suspicious lesion and near its proximal border. The biopsy gun trigger should, then, be activated and the

examiner should see the cutting interior part of the needle traversing the lesion. This process should be repeated 3 times for each suspicious lesion, targeting different parts of the lesion, to assure that enough tissue is extracted for pathology analysis. To assess the extent of each lesion, additional tissue from near the edges of the lesion towards the apex and the base of the gland, should be extracted.

Subsequently, to prove or exclude the presence of multi-focal adenocarcinoma, at least 4 cores should be extracted from the TZ, prioritizing segments that are not accessible through TRUS and Elastography. Moreover, at least 6 cores should be extracted from the PZ and TZ on the opposite side of the detected lesion.

When targeting PZ hypo-echoic lesions that are in contact with the Prostate's capsule, the examiner should place the edge of the needle 3-4mm away from the lesion to assure that the specimen contains capsule and periprostatic fat tissue. This is vital, as it may prove or exclude invasion of the capsule and the periprostatic fat by the tumor. It is recommended that at least 2cm of specimen is extracted [21, 22]. The examiner may choose the maximum specimen length, unless there is a risk of injuring the urethra or bladder neck. According to the literature 10-22 core schemes may be used in Prostate Biopsies without limiting the accuracy in PrCa detection [23].

After extracting tissue from all suspicious lesions and before removing the probe from the rectum, the examiner should compress the Prostate, using the lateral part of the transducer for 2 minutes, to limit the possibility of periprostatic of rectal hemorrhage.

2.3.7 Complications

TRUS Guided biopsies are associated with complications, such as rectal hemorrhage, fever, sepsis, hematuria, hematospermia, acute urinary retention and vagotonia [19].

The most common Prostate Biopsy complication is initial mild hematuria, which occurs for practically all patients and may last for several days. However, severe hematuria can be avoided in most cases since the examiner can reliably visualize the urethra and the neck of the bladder with B-Mode and Elastography and, therefore, avoid traumatizing them. Hematospermia is another very common transrectal biopsy complication, which requires no treatment. Sexual abstinence for a week is advised. Rectal hemorrhage is another complication, which can be avoided with an appropriately applied post-biopsy compression of the Prostate. In case of late recurrence an endoscopic ligation is indicated. Vagotonia may occur just after the end of the biopsy procedure, especially if the patient tries to urinate immediately after the procedure. Vagotonia may cause the patient to faint. The patient must stay in horizontal position for 15 min. Sepsis and fever may occur in rare cases of prostatitis due to insertion of intestinal microbes in the Prostate and, consequently, in the bloodstream, causing septicemia. The possibility of sepsis can be largely limited through adequate rectal antisepsis before performing a Prostate Biopsy. Hospitalization is necessary when sepsis occurs, as it could be life-threatening.

2.3.8 MpMRI/TRUS Fusion Guided Biopsy

MpMRI combines morphologic, hemodynamic and metabolic information to visualize most of the PrCas in both PZ and TZ and classify them under the PIRADS system (1-5 as the possibility of presence of PrCa increases) [24].

MpMRI/TRUS Fusion is a technique designed to combine the advantages of the TRUS and MpMRI modalities in detecting and classifying suspicious Prostate lesions. The combination is accomplished by over-imposing pre-selected MRI images on TRUS real time images during the US guided prostate biopsy performance. The result of this combination in

TRUS-guided Prostate biopsies is a 3D image of the entire Prostate that helps in detecting and targeting all, visible through TRUS and Mp-MRI, lesions.

The combination of MpMRI and TRUS B-Mode may be time consuming and challenging, since the Prostate's shape is altered during a Prostate biopsy, mainly due to the positioning of the rectal probe. MpMRI/TRUS Fusion, however, may drastically limit the number of saturation biopsies and the resulting complications, since it offers the possibility of targeting specific suspicious lesions. The main MpMRI advantage over TRUS is its ability to reliably visualize TZ and CZ lesions, where TRUS and Elastography have limited differentiating capacity. It is important to emphasize, however, that the majority of PrCas are located in the PZ.

Despite its advantages, the use of TRUS/MRI Fusion during Prostate biopsies is not indispensable. On the contrary MRI examination findings may be utilized by the examiner in order to target, invisible through US, lesions in the TZ and to corroborate suspicious lesions in the PZ. If the findings of TRUS and MRI regarding the existence and location of a lesion coincide, it should be definitely targeted for a biopsy. "Cognitive fusion" is the process during which the US operator aims the biopsy needle at a prostate area where the previously performed and reviewed MRI examination demonstrates a lesion [25, 26].

2.3.9 Transperineal Biopsy

In transperineal Prostate biopsies the needle is guided by a rectal biplane probe, through a dedicated gridding guide placed on the probe and the perineum. The linear part of the biplane probe is used because its US beam is parallel to the needle trajectory, rendering the guidance easy and reliable.

In transperineal biopsies the need for fluoroquinolone prophylactics is eliminated, as the needle passes

through the perineum instead of the rectum [18]. The procedure is also considered safer for patients prone to infection, have prostatitis or urinary catheterization, and diabetic patients [19]. Transperineal biopsies are considered superior to transrectal biopsies in targeting apical and anterior Prostate regions [27], as this positioning entails very challenging needle guidance through TRUS and Elastography due to the distance between the tumor and the transducer. The perineum, on the other hand, is conveniently located in front of the lesions in the anterior TZ and ensures adequate tissue specimen extraction.

Transperineal biopsies, however, are associated with multiple drawbacks when compared to transrectal biopsies, such as the need for general anesthesia, inconvenience, time consumption and high cost [27].

2.3.10 Prostate Cancer Histology

The Gleason score pathology system was introduced to classify PrCas based on malignancy and aggressiveness. The system mainly relies on malignant cells arrangement and factors like the degree of differentiation. A less glandular appearance leads to a higher Gleason grade. A Gleason grade 1 would mean normal appearance and a grade 5 would mean abnormal cells with absence of glandular features [28]. A total score is calculated based on how cells look under a microscope, with the first half of the score based on the dominant, or most common cell morphology (scored 1 to 5), and the second half based on the non-dominant cell pattern with the highest grade (scored 1 to 5). These two numbers are then added to produce a total score for the cancer [28, 29]. In order for the Gleason Score to be representative of a particular tumor, 3-4 biopsies have to be taken from the PrCa.

Gleason Score 3+3=6 is considered a marginal malignant tumor and a "watchful waiting" approach may be chosen. This non-aggressive approach may

help limiting the aggressive (prostatectomy and/or radiotherapy) PccCa treatment and the resulting cost, since these tumors may never affect a patient's quality or length of life. Good technique of acquiring enough tissue for a PrCa is a prerequisite for classifying the PrCa reliably and, therefore, avoiding over-diagnosis and over-treatment issues.

3. Resona 7 TRUS Examination & Prostate Biopsy Step-by-Step

1. Patient preparation

Stop anticoagulant treatment, antibiotic treatment, cleansing Enema, rectal antiseptic, local anesthesia

2. Probe preparation

Two covers, no air in the gel between covers, antiseptic gel in the rectum

3. TRUS examination

Visualize PZ and TZ through longitudinal and transverse sections, locate hypoechoic lesions in the PZ

4. Elastography

Assess stiffness of suspicious lesions in both PZ and TZ using both Strain and SWE/STE when applicable:

STE: Press the Elastography button, place the transducer as close to the lesion as possible, adjust the transducer so that the lesion is located in the middle of the US section, position the STE ROI to include the lesion, press the Update button, wait for the STE color box to stabilize, compare the stiffness of the lesion and the surrounding PZ parenchyma, adjust the color map accordingly so that the stiffness lesion-parenchyma

comparison is possible, assess the stability index and repeat the process if necessary

Strain: Press the Elastography button, press the Strain button on the touch screen, place the transducer as close to the lesion as possible, adjust the transducer so that the lesion is located in the middle of the US section, position the Strain ROI to include the lesion, perform small periodical compressions using the transducer, assess the index bar and repeat the process if necessary

5. TRUS guided biopsy:

Start targeting the main US and SWE/STE visible lesion, 3-4 cores from the lesion may facilitate pathology scoring, place the edge of the needle 2-3mm from the proximal edge of each lesion and activate the biopsy gun trigger (the needle should penetrate and pass through the lesion), include capsule and periprostatic fat in 2 cores to prove invasion, withdraw the biopsy gun and place the specimen on the sponge of the pathology specimen cassette, guide the needle in other suspicious or challenging lesions, extract specimens (3-4 cores) from the opposite from the principal tumor side for staging purposes even if no lesion is visible

6. Avoiding hemorrhage:

Apply compression using the longitudinal lateral part of the probe (not the edge where the convex US array is located) for 2 min.

7. Avoiding vagotonia and trauma:

The patient must stay lying down for 15 min after the procedure

4. Interesting Cases

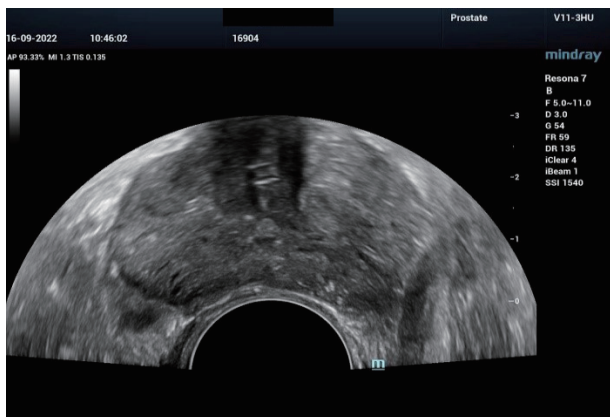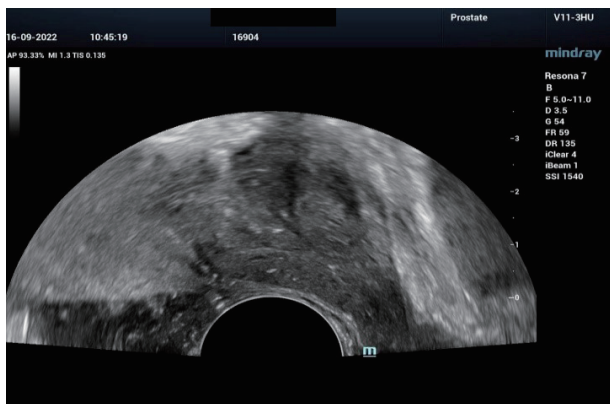Interesting Case 1

Clinical information: no symptoms

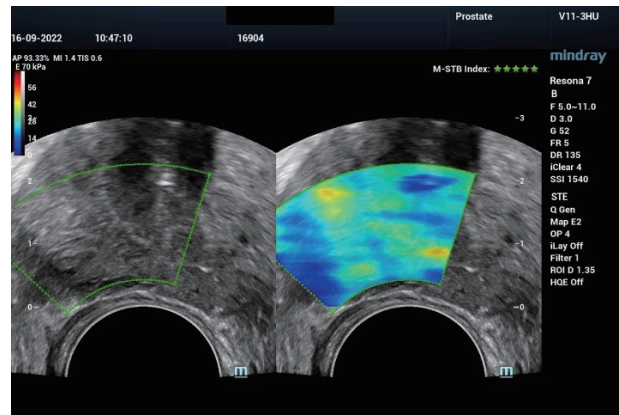
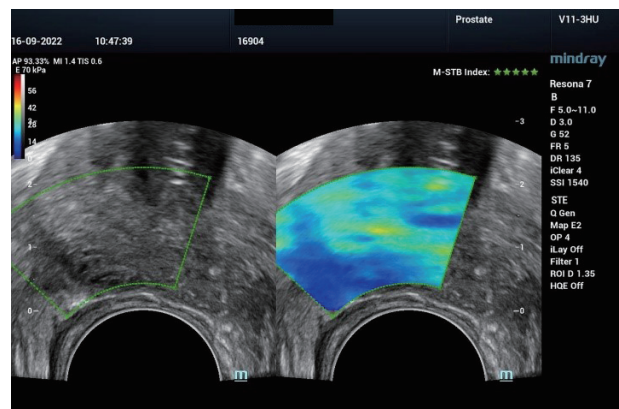
Biochemical: recent 3.4 ngr PSA examination

TRUS: Normal PZ, mild prostate hypertrophy

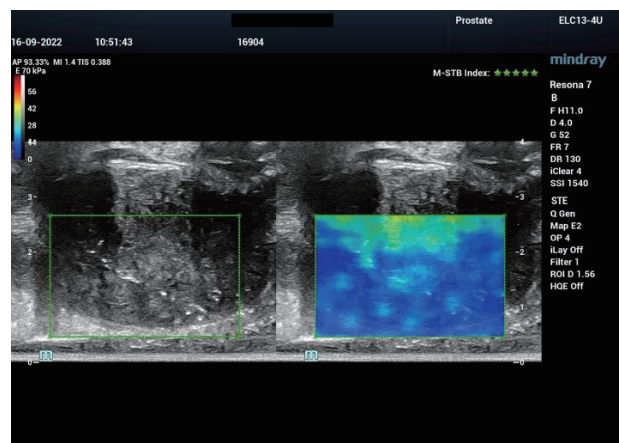
Histological: Benign Prostate hyperplasia



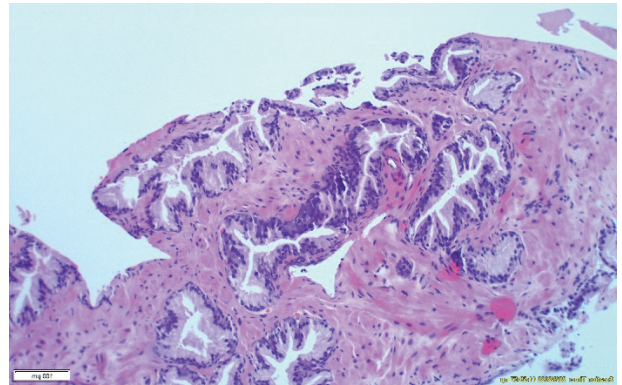
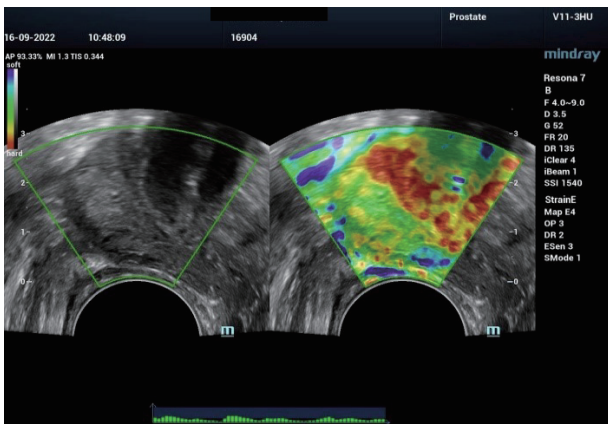
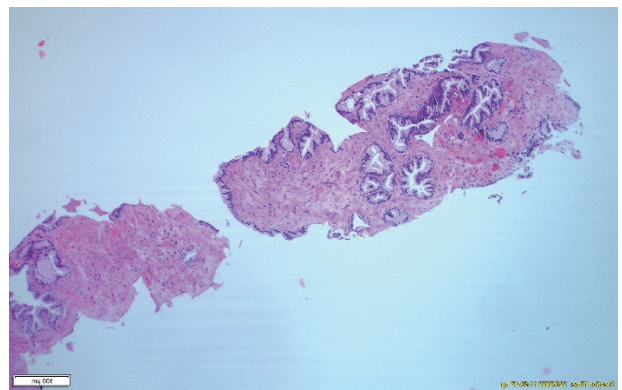
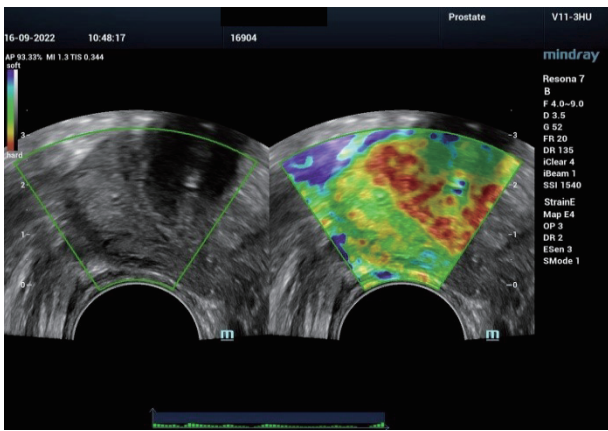
Up: V11-3HU probe longitudinal section. Down: V11-3HU probe transverse section



V11-3HU probe (STE): normal PZ (dark blue)-TZ (green-yellow) differentiation



ELC13-4U probe STE longitudinal section: normal PZ (dark blue)-TZ (green) differentiation



Histology examination: benign Prostate hyperplasia

V11-3HU probe Strain Elastography transverse sections: normal PZ (green)- TZ (red) differentiation

Interesting Case 2

Clinical information: mild Prostate hypertrophy

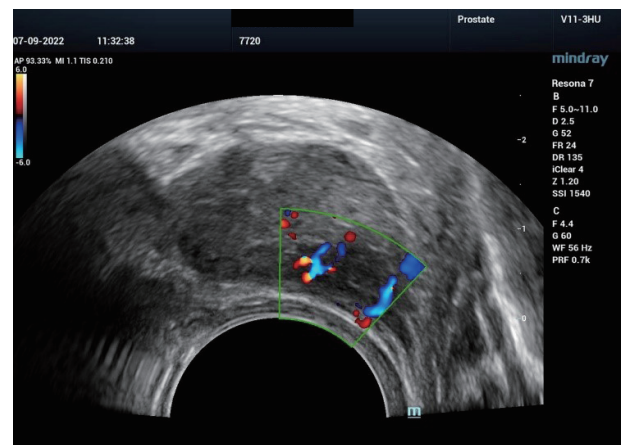
Biochemical: recent 7.8 ngr PSA examination

MRI: Pirads 4 in the left PZ in the apex of the gland

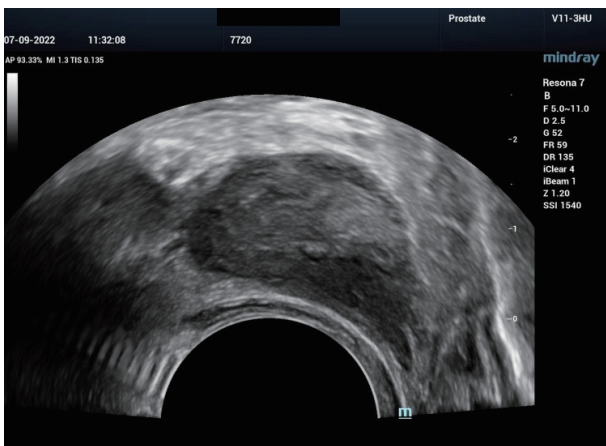
TRUS: hypo-echoic PZ lesion in the apex of the gland

Histological: Gleason 7 (3+4) PrCa

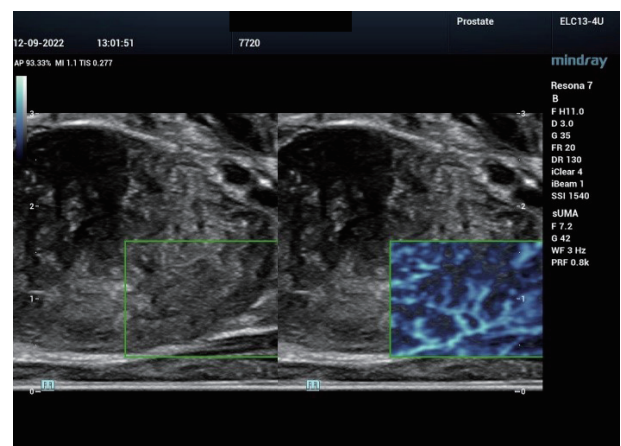
Comments: typical PrCa B-Mode and Elastographic appearance



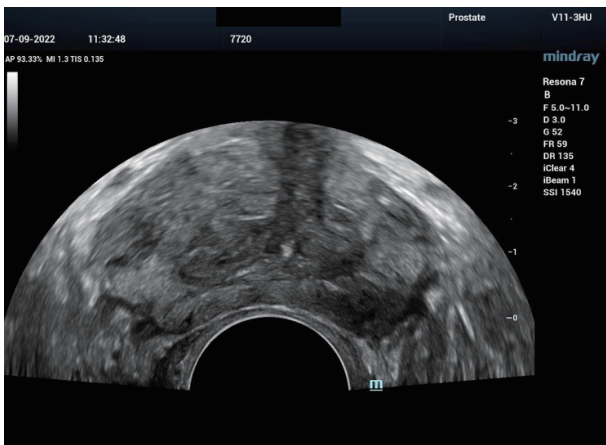V11-3HU transducer longitudinal section (Color Doppler)



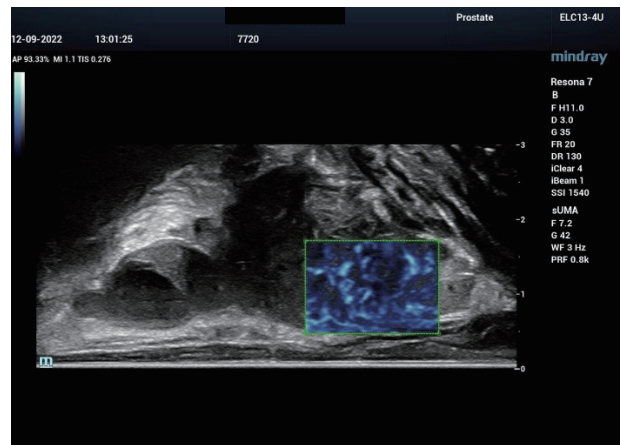
V11-3HU transducer longitudinal section



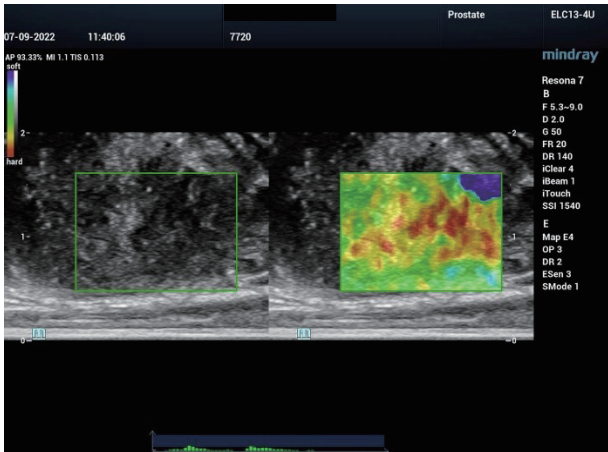
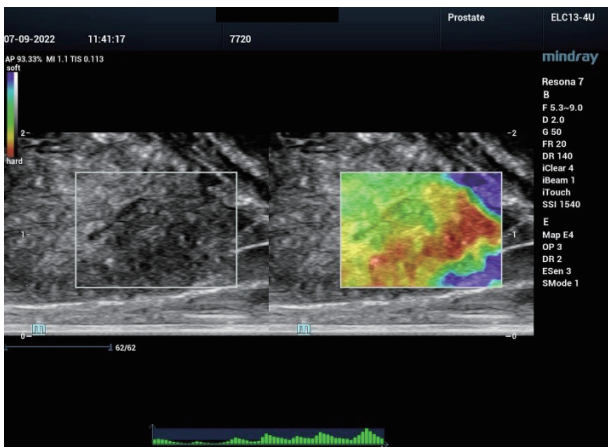
ELC13-4U transducer (linear part) longitudinal section (UMA)



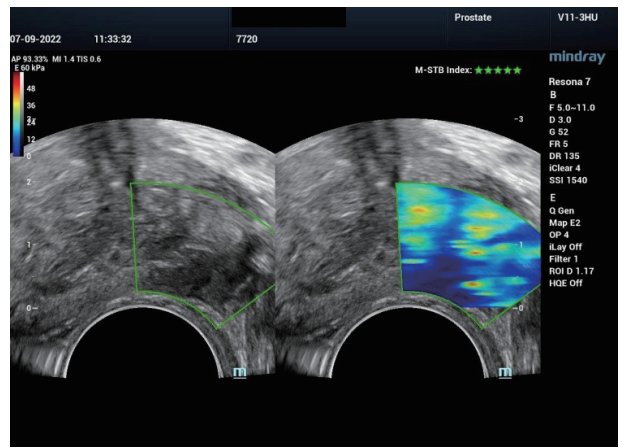
V11-3HU transducer transversal section



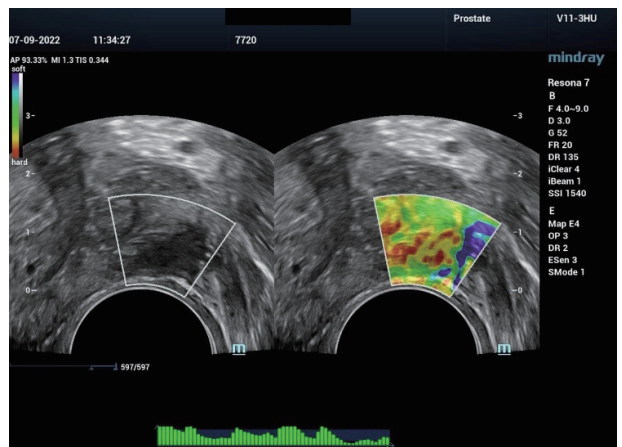
ELC13-4U transducer (linear part) longitudinal (UMA). Neo-vessels inside the tumor are a typical PrCa finding



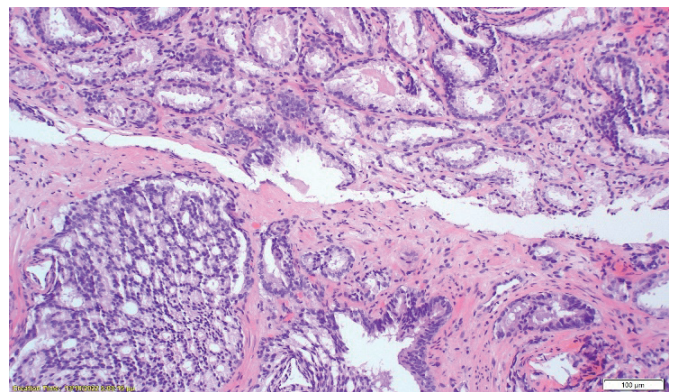
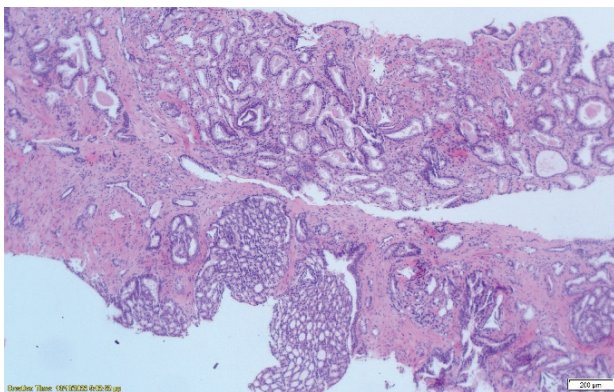
ELC13-4U transducer (linear part) longitudinal section (Strain Elastography). The hypo-echoic tumor appears stiff (red).



V11-3HU transducer transverse section (STE) Dark blue color coding indicates increased stiffness



V11-3HU transducer transverse section (Strain Elastography). The hypo-echoic PrCa appears stiff (red) in strain Elastography



Histology examination: Gleason 7 (3+4) PrCa

Interesting Case 3

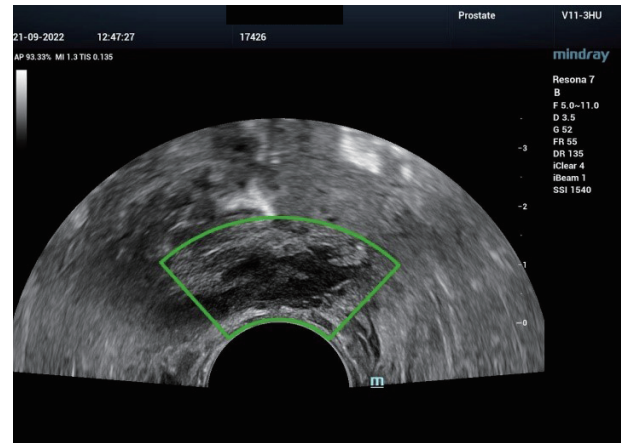
Clinical information: Prostate Hypertrophy. Atypical findings in DRE

Biochemical: recent 9.4 ngr PSA examination

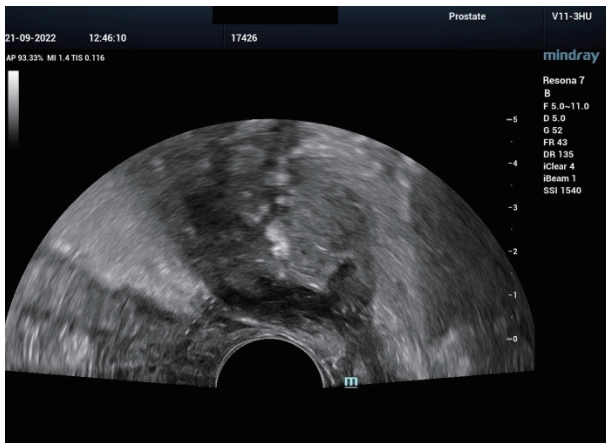TRUS: lobular hypo-echoic lesion in the left PZ and TZ from the apex through the base of the gland, invading the seminal vesicles

Histological: Gleason score 8 (4+4) PrCa

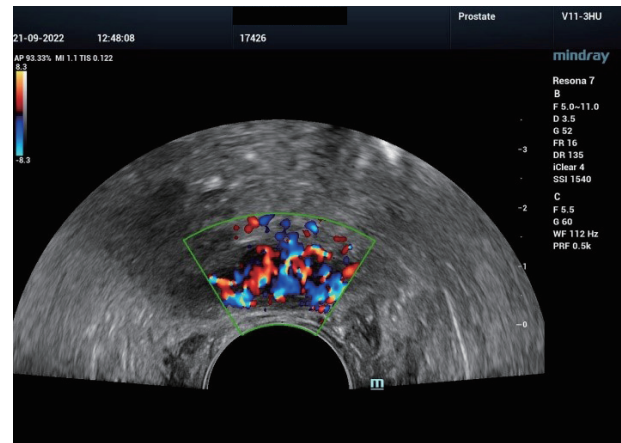Comments: typical large hypo-echoic PrCa with typical B-Bode and Elastographic findings



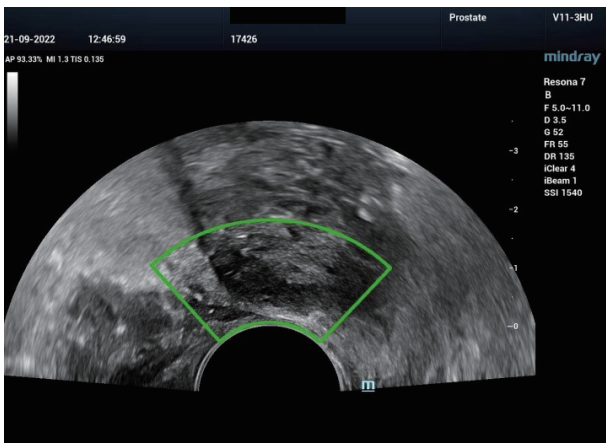
V11-3HU transducer transversal section (HD scope)



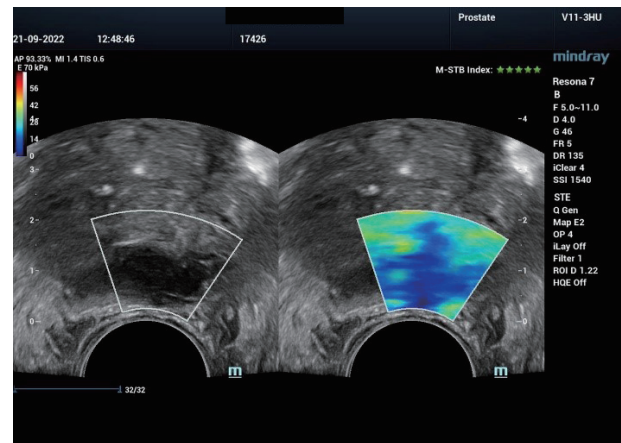V11-3HU transducer longitudinal section



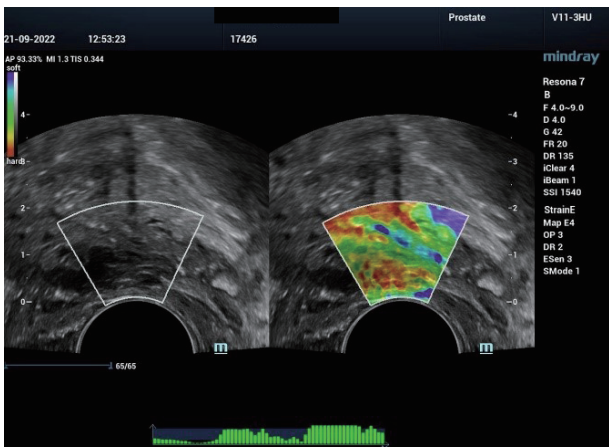
V11-3HU transducer longitudinal section (Color Doppler)



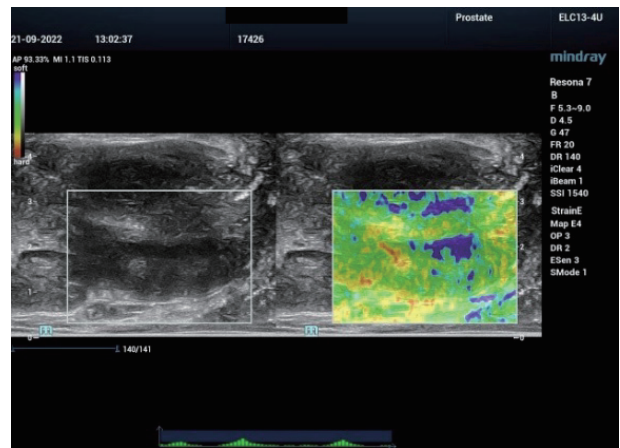
V11-3HU transducer longitudinal section (HD scope)



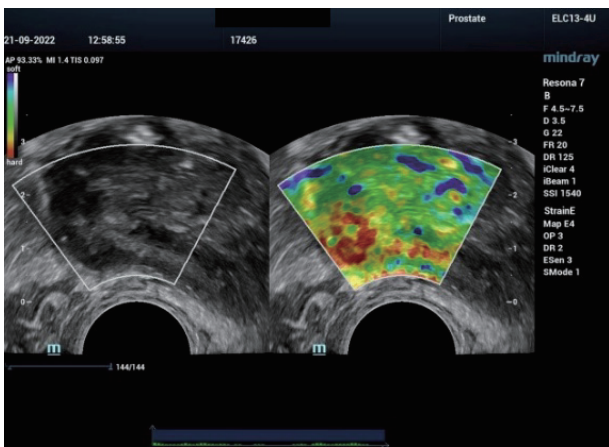
V11-3HU transducer transversal section (STE). Dark blue indicates increased stiffness



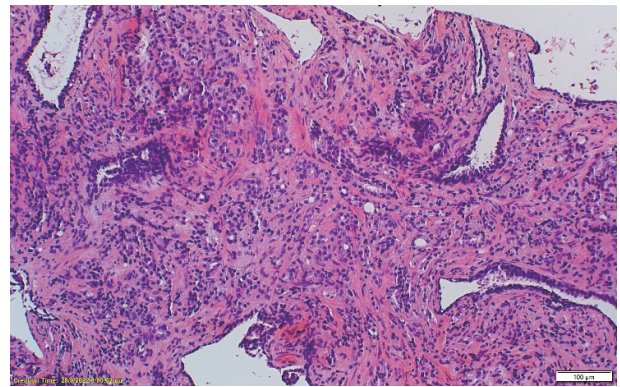
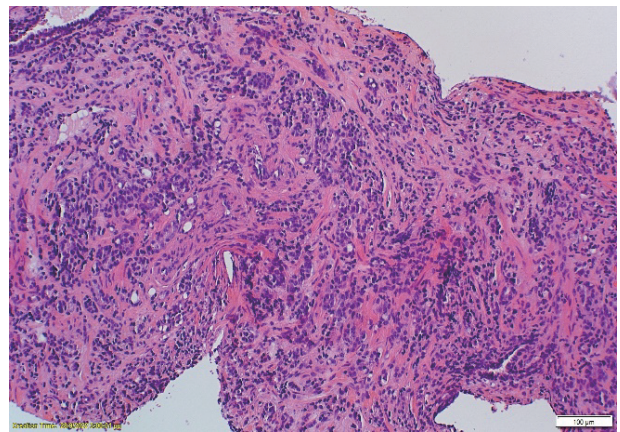
V11-3HU transducer transversal section (Strain Elastography). The tumor appears stiff (red).



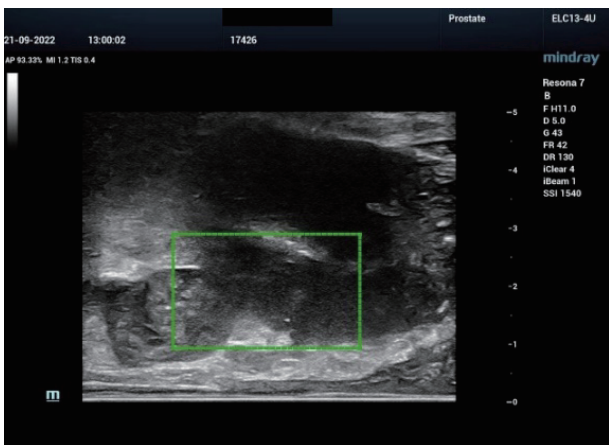
ELC13-4U transducer (linear part) longitudinal section (Strain Elastography). The partial dark blue color coding indicates increased stiffness.



ELC13-4U transducer (convex part) transversal section (Strain Elastography). The tumor appears stiff (red).



Histology examination: Gleason score 8 (4+4) PrCa



ELC13-4U transducer (linear part) longitudinal section (HD scope). Seminal vesicle invasion.

Interesting Case 4

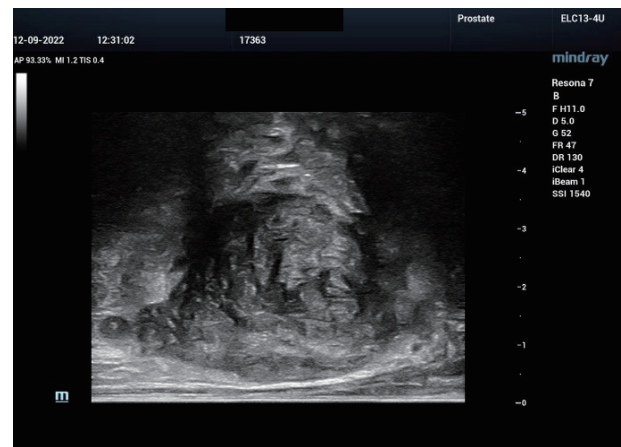
Clinical information: Important Prostate Hypertrophy

Biochemical: recent 6.8 ngr PSA examination

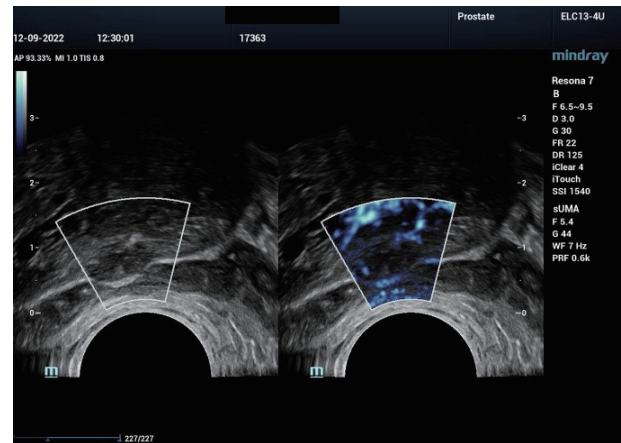
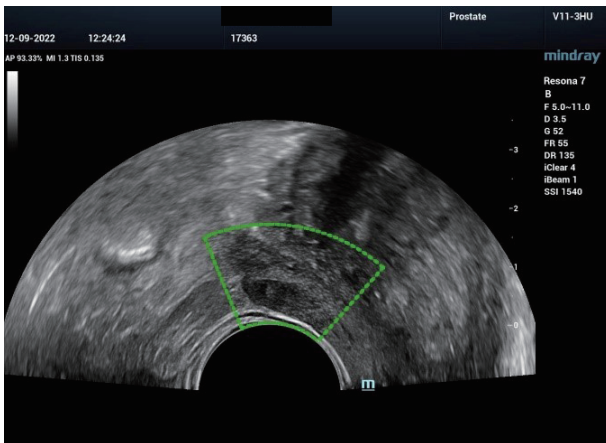
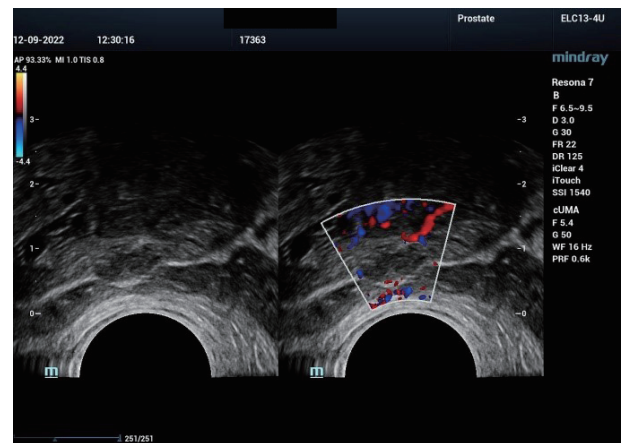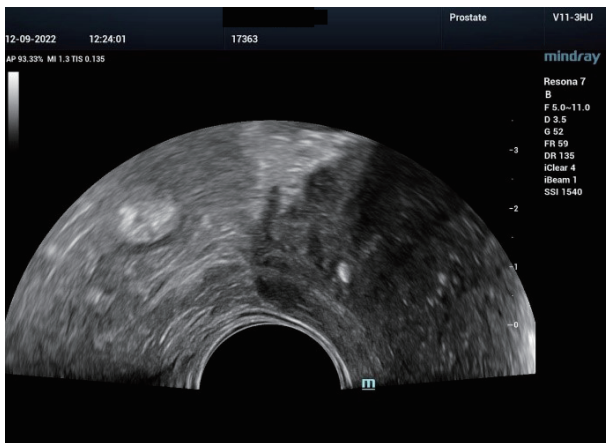TRUS: small hypo-echoic lesion in the right PZ in the base of the gland

Histological: Gleason score 6 (3+3) PrCa

Comments: typical small hypo-echoic PrCa with typical B-Bode and Elastographic findings

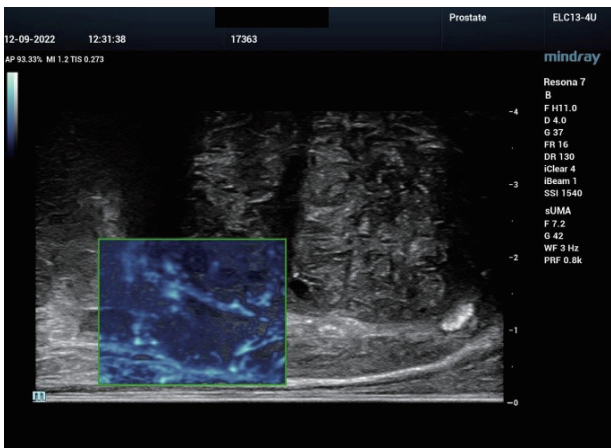


ELC13-4U probe (linear part) probe longitudinal section.

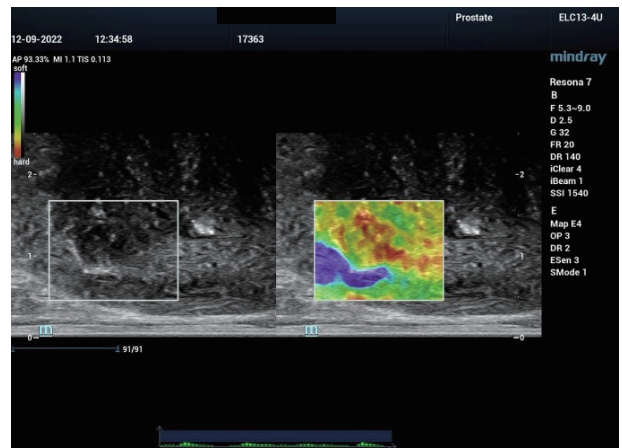


V11-3HU probe transverse sections. Down: HD Scope

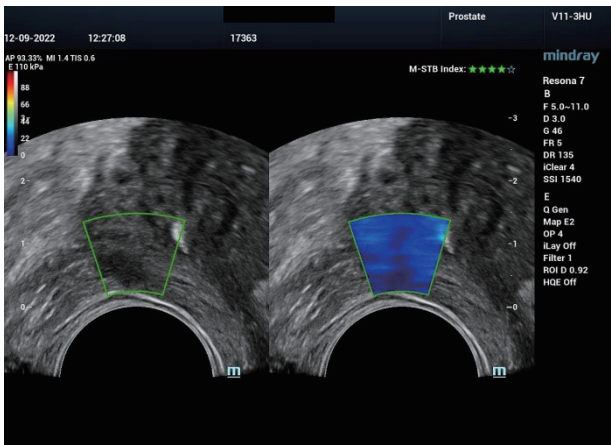
ELC13-4U (convex part): hypo-vascular tumor with neo vessels in the periphery.



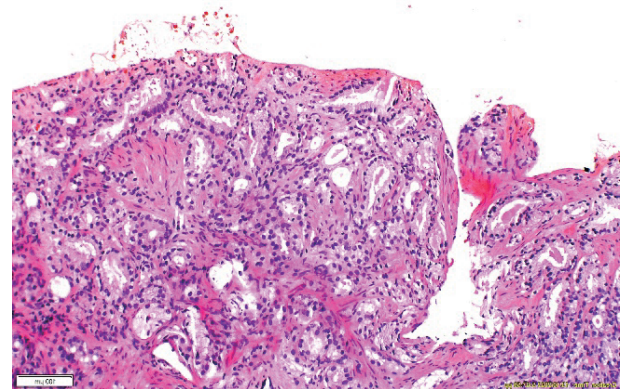
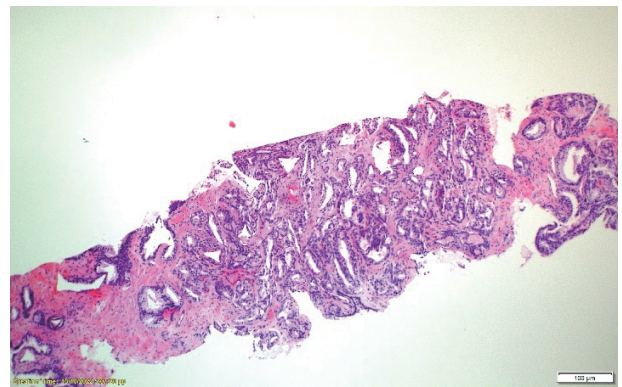
ELC13-4U (linear part): hypo-vascular tumor with neo vessels in the periphery.



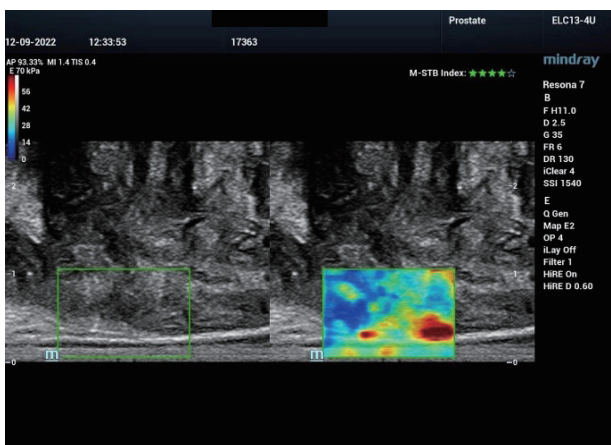
ELC13-4U probe (linear part) (Strain Elastography) longitudinal section. Part of the tumor appears stiff (red) and Dark blue, indicating increased stiffness.



V11-3HU probe (STE) transversal section. Dark blue color coding indicates increased stiffness.



Histology examination: Gleason score 6 (3+3) PrCa



V11-3HU probe linear part (STE) longitudinal section. Dark blue color coding indicates increased stiffness.

5. References

1. Barr RG, Cosgrove D, Brock M, Cantisani V, Correas JM, Postema AW, Salomon G, Tsutsumi M, Xu HX, Dietrich CF. WFUMB Guidelines and Recommendations on the Clinical Use of Ultrasound Elastography: Part 5. Prostate. *Ultrasound Med Biol*. 2017 Jan;43(1):27-48. doi: 10.1016/j.ultrasmedbio.2016.06.020. Epub 2016 Aug 25. PMID: 27567060.
2. Cosgrove D, Piscaglia F, Bamber J, Bojunga J, Correas JM, Gilja OH, Klauser AS, Sporea I, Calliada F, Cantisani V, D'Onofrio M, Drakonaki EE, Fink M, Friedrich-Rust M, Fromageau J, Havre RF, Jenssen C, Ohlinger R, Săftoiu A, Schaefer F, Dietrich CF; EFSUMB. EFSUMB guidelines and recommendations on the clinical use of ultrasound elastography. Part 2: Clinical applications. *Ultraschall Med*. 2013 Jun;34(3):238-53. doi: 10.1055/s-0033-1335375. Epub 2013 Apr 19. PMID: 23605169.
3. Dietrich CF. EFSUMB guidelines 2015 on interventional ultrasound. *Med Ultrason*. 2015 Dec;17(4):521-7. doi: 10.11152/mu.2013.2066.174.e. PMID: 26649349.
4. Lee MS, Moon MH, Kim CK, Park SY, Choi MH, Jung SI; Korean Society of Urogenital Radiology (KSUR). Guidelines for Transrectal Ultrasonography-Guided Prostate Biopsy: Korean Society of Urogenital Radiology Consensus Statement for Patient Preparation, Standard Technique, and Biopsy-Related Pain Management. *Korean J Radiol*. 2020 Apr;21(4):422-430. doi: 10.3348/kjr.2019.0576. PMID: 32193890; PMCID: PMC7082664.
5. Ward E, Baad M, Peng Y, Yousuf A, Wang S, Antic T, Oto A. Multi-parametric MR imaging of the anterior fibromuscular stroma and its differentiation from prostate cancer. *Abdom Radiol (NY)*. 2017 Mar;42(3):926-934. doi: 10.1007/s00261-016-0951-0. PMID: 27766349.
6. Lee JJ, Thomas IC, Nolley R, Ferrari M, Brooks JD, Leppert JT. Biologic differences between peripheral and transition zone prostate cancer. *Prostate*. 2015 Feb;75(2):183-90. doi: 10.1002/pros.22903. Epub 2014 Oct 18. PMID: 25327466; PMCID: PMC4270836
7. Ellis WJ, Brawer MK. The significance of isoechoic prostatic carcinoma. *J Urol*. 1994 Dec;152(6 Pt 2):2304-7. doi: 10.1016/s0022-5347(17)31663-4. PMID: 7526001.
8. Chen FK, de Castro Abreu AL, Palmer SL. Utility of Ultrasound in the Diagnosis, Treatment, and Follow-up of Prostate Cancer: State of the Art. *J Nucl Med*. 2016 Oct;57(Suppl 3):13S-18S. doi: 10.2967/jnumed.116.177196. PMID: 27694164.
9. Zhao C, Wang Q, Wang M, Tao X, Liu S, Qi Z, Lanxi X, Liu D, He X, Tian X, Zeng X, Jiang Y, Yang M. Ultra-microangiography in evaluating the disease activity of rheumatoid arthritis and enhancing the efficacy of ultrasonography: A preliminary study. *Eur J Radiol*. 2021 Apr;137:109567. doi: 10.1016/j.ejrad.2021.109567. Epub 2021 Jan 26. PMID: 33556758.
10. Bamber J, Cosgrove D, Dietrich CF, Fromageau J, Bojunga J, Calliada F, Cantisani V, Correas JM, D'Onofrio M, Drakonaki EE, Fink M, Friedrich-Rust M, Gilja OH, Havre RF, Jenssen C, Klauser AS, Ohlinger R, Saftoiu A, Schaefer F, Sporea I, Piscaglia F. EFSUMB guidelines and recommendations on the clinical use of ultrasound elastography. Part 1: Basic principles and technology. *Ultraschall Med*. 2013 Apr;34(2):169-84. doi: 10.1055/s-0033-1335205. Epub 2013 Apr 4. PMID: 23558397.
11. Shiina T, Nightingale KR, Palmeri ML, Hall TJ, Bamber JC, Barr RG, Castera L, Choi BI, Chou YH, Cosgrove D, Dietrich CF, Ding H, Amy D, Farrokhi A, Ferraioli G, Filice C, Friedrich-Rust M, Nakashima K, Schafer F, Sporea I, Suzuki S, Wilson S, Kudo M. WFUMB guidelines and recommendations for clinical use of ultrasound elastography: Part 1: basic principles and terminology. *Ultrasound Med Biol*. 2015 May;41(5):1126-47. doi: 10.1016/j.ultrasmedbio.2015.03.009. Epub 2015 Mar 21. PMID: 25805059.
12. Sigrist RMS, Liao J, Kaffas AE, Chammas MC, Willmann JK. Ultrasound Elastography: Review of Techniques and Clinical Applications. *Theranostics*. 2017 Mar 7;7(5):1303-1329. doi: 10.7150/thno.18650. PMID: 28435467; PMCID: PMC5399595.
13. Dietrich CF, Bamber J, Berzigotti A, Bota S, Cantisani V, Castera L, Cosgrove D, Ferraioli G, Friedrich-Rust M, Gilja OH, Goertz RS, Karlas T, de Knecht R, de Ledinghen V, Piscaglia F, Procopet B, Saftoiu A, Sidhu PS, Sporea I, Thiele M. EFSUMB Guidelines and Recommendations on the Clinical Use of Liver Ultrasound Elastography, Update 2017 (Long Version). *Ultraschall Med*. 2017 Aug;38(4):e16-e47. English. doi: 10.1055/s-0043-103952. Epub 2017 Apr 13. Erratum in: *Ultraschall Med*. 2017 Aug;38(4):e48. PMID: 28407655.
14. Ferraioli G, Wong VW, Castera L, Berzigotti A, Sporea I, Dietrich CF, Choi BI, Wilson SR, Kudo M, Barr RG. Liver Ultrasound Elastography: An Update to the World Federation for Ultrasound in Medicine and Biology Guidelines and Recommendations. *Ultrasound Med Biol*. 2018 Dec; 44(12):2419-2440. doi: 10.1016/j.ultrasmedbio.2018.07.008. Epub 2018 Sep 9. PMID: 30209008.

15. Barr RG, Memo R, Schaub CR. Shear wave ultrasound elastography of the prostate: initial results. *Ultrasound Q*. 2012 Mar;28(1):13-20. doi: 10.1097/RUQ.0b013e318249f594. PMID: 22357224.
16. Woo S, Kim SY, Cho JY, Kim SH. Shear wave elastography for detection of prostate cancer: a preliminary study. *Korean J Radiol*. 2014 May-Jun;15(3):346-55. doi: 10.3348/kjr.2014.15.3.346. Epub 2014 Apr 29. Erratum in: *Korean J Radiol*. 2015 Nov-Dec;16(6):1373. PMID: 24843239; PMCID: PMC4023053.
17. Woo S, Kim SY, Cho JY, Kim SH. Shear wave elastography for detection of prostate cancer: a preliminary study. *Korean J Radiol*. 2014 May-Jun;15(3):346-55. doi: 10.3348/kjr.2014.15.3.346. Epub 2014 Apr 29. Erratum in: *Korean J Radiol*. 2015 Nov-Dec;16(6):1373. PMID: 24843239; PMCID: PMC4023053.
18. Grummet J, Pepdjonovic L, Huang S, Anderson E, Hadaschik B. Transperineal vs. transrectal biopsy in MRI targeting. *Transl Androl Urol*. 2017 Jun;6(3):368-375. doi: 10.21037/tau.2017.03.58. PMID: 28725578; PMCID: PMC5503965.
19. Xiang J, Yan H, Li J, Wang X, Chen H, Zheng X. Transperineal versus transrectal prostate biopsy in the diagnosis of prostate cancer: a systematic review and meta-analysis. *World J Surg Oncol*. 2019 Feb 13;17(1):31. doi: 10.1186/s12957-019-1573-0. PMID: 30760274; PMCID: PMC6375152.
20. Gottschalk A, Van Aken H, Zenz M, Standl T. Is anesthesia dangerous? *Dtsch Arztebl Int*. 2011 Jul;108(27):469-74. doi: 10.3238/arztebl.2011.0469. Epub 2011 Jul 8. PMID: 21814522; PMCID: PMC3147285.
21. El-Hakim A, Moussa S. CUA guidelines on prostate biopsy methodology. *Can Urol Assoc J*. 2010 Apr;4(2):89-94. doi: 10.5489/cuaj.10021. PMID: 20368888; PMCID: PMC2845759.
22. Kaye KW. Prostate biopsy using automatic gun. Technique for determination of precise biopsy site. *Urology*. 1989 Aug;34(2):111-2. doi: 10.1016/0090-4295(89)90177-5. PMID: 2669307.
23. Eichler K, Hempel S, Wilby J, Myers L, Bachmann LM, Kleijnen J. Diagnostic value of systematic biopsy methods in the investigation of prostate cancer: a systematic review. *J Urol*. 2006 May;175(5):1605-12. doi: 10.1016/S0022-5347(05)00957-2. PMID: 16600713.
24. Woo S, Suh CH, Kim SY, Cho JY, Kim SH, Moon MH. Head-to-Head Comparison Between Biparametric and Multiparametric MRI for the Diagnosis of Prostate Cancer: A Systematic Review and Meta-Analysis. *AJR Am J Roentgenol*. 2018 Nov;211(5):W226-W241. doi: 10.2214/AJR.18.19880. Epub 2018 Sep 21. PMID: 30240296.
25. Marks L, Young S, Natarajan S. MRI-ultrasound fusion for guidance of targeted prostate biopsy. *Curr Opin Urol*. 2013 Jan;23(1):43-50. doi: 10.1097/MOU.0b013e32835ad3ee. PMID: 23138468; PMCID: PMC3581822.
26. Moore CM, Robertson NL, Arsanious N, Middleton T, Villers A, Klotz L, Taneja SS, Emberton M. Image-guided prostate biopsy using magnetic resonance imaging-derived targets: a systematic review. *Eur Urol*. 2013 Jan;63(1):125-40. doi: 10.1016/j.eururo.2012.06.004. Epub 2012 Jun 13. PMID: 22743165.
27. Patel, P. The case for transperineal prostate biopsy vs. the transrectal approach. *Urology Times*. 2020 Feb;48(2):16-17.
28. Gleason DF. Classification of prostatic carcinomas. *Cancer Chemother Rep*. 1966 Mar;50(3):125-8. PMID: 5948714.
29. Pierorazio PM, Walsh PC, Partin AW, Epstein JI. Prognostic Gleason grade grouping: data based on the modified Gleason scoring system. *BJU Int*. 2013 May;111(5):753-60. doi: 10.1111/j.1464-410X.2012.11611.x. Epub 2013 Mar 6. PMID: 23464824; PMCID: PMC3978145.