

Ultrasound Journal

A Case Sharing of Prostate Shearwave Elastography

Case 3



A special thanks for sharing this case to Dr. Nguyen Minh Thien of The Urology Department of Ho Chi Minh Medic Center.

1 - Case Introduction

A 71 YO male patient coming for prostate cancer screening, PSA levels higher than 100ng/ml. DRE showed an enlarged prostate with a hard nodule on the right lobe.



2 - 2D and Color Ultrasound findings

Due to its anatomical location, it is recommended that a prostate ultrasound examination be conducted using real-time transrectal ultrasound (TRUS) with the highest frequency biplane endocavitary transducer (Mindray Resona i9, ELC13-4)

Prostate scanning was performed with a Mindray dedicated biplane convex-linear ultrasound probe. The transducer contains 2 ultrasound probes: the convex array and the linear array. The transverse image of the prostate was obtained with the convex array and the longitudinal image of the prostate was obtained with the linear array. Convex and linear arrays were supported with both Elastography techniques including: Strain Elastography (NTE, Natural Touch Elastography) and 2D Shearwave Elastography (SWE, Sound Touch Elastography).

Ultrasound Findings of right lobe of the prostate:

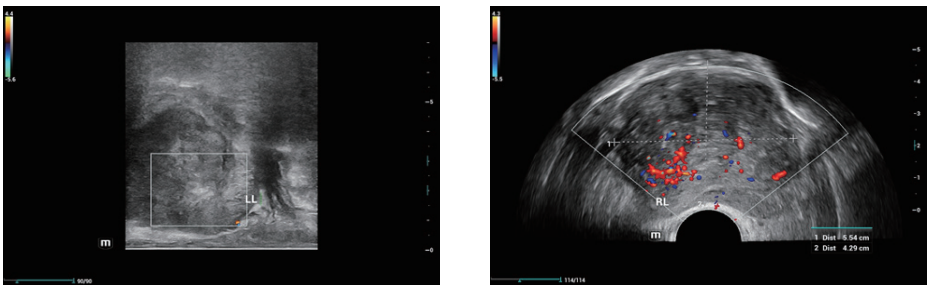


Fig 1&2. The 2D Ultrasound found a suspicious hypoechoic nodule with hypervascularity in the peripheral zone of the right lobe and irregular capsule

Ultrasound Findings of left lobe of the prostate:

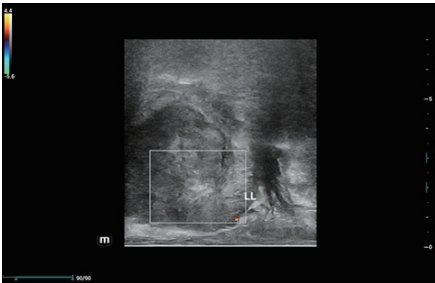


Fig 3. TRUS on left lobe showed some normal findings: no suspicious nodule area, normal doppler signs, but the prostate capsule was not clear and smooth as normal.

3 - Elastography Findings

NTE – Strain Elastography

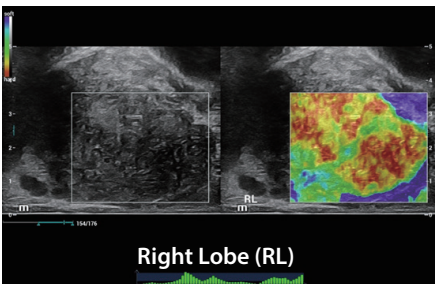


Fig 4. SE on RL showed the very stiff area linked to the hypoechoic focal nodular finding, Kamoi Score No.5, and E/B ratio > 1.

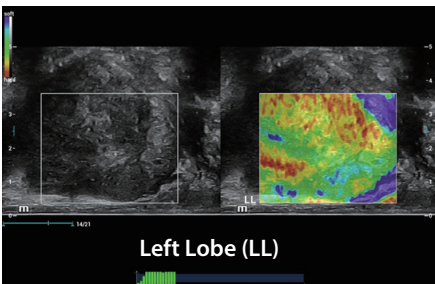


Fig 5. The finding on left lobe was a typical normal finding with a well-defined border between the transition zone (TZ) and the peripheral zone (PZ). PZ elastogram was normal soft map.

SWE – Shear Wave Elastography

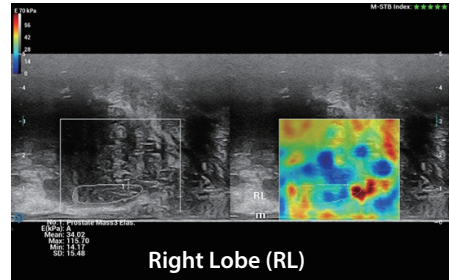


Fig 6. The stiffness measurement results of PZ of RL were:

Mean value:	34kPa
Maximum value:	115kPa

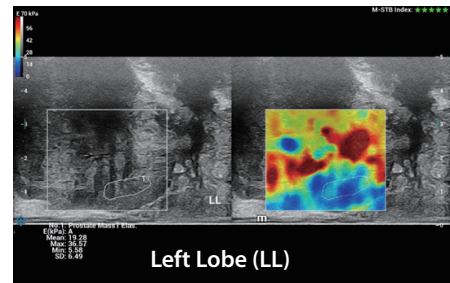


Fig 7. The SWE found some normal findings of LL of the prostate, including normal soft elastogram in PZ, TZ was stiffer than PZ in the elderly patient, can distinguish well the boundary between TZ and PZ

Mean value:	19kPa
Maximum value:	36kPa

The stiffness measurement results on PZ of RL were quite soft when compared with RL.

4 - Biopsy Result

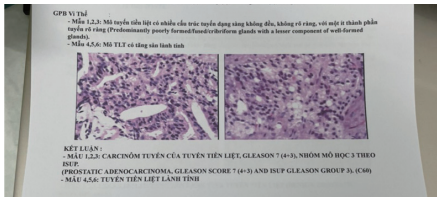


Fig 8. Biopsy Results

A 6-core biopsy was done. Tissue sample numbers 1 to 3 were taken from the right lobe, and numbers 4-6 were taken from the left lobe.

The Biopsy Results Were

1,2,3: PROSTATIC ADENOCARCINOMA, Gleason score 7 (4+3), ISUP Gleason group 3 (C60): predominantly poorly formed/fused/ciribriform glands with a lesser component of well-formed glands.

4,5,6: Normal prostate tissue.

4 - Discussion

• Case introduction

PCa Screening on an elderly patient who had abnormal high PSA value (>100ng/ml) and abnormal DRE results (enlarged prostate and stiff nodule on RL)

• Ultrasound

2D and Color Ultrasound showed a suspicious hypoechoic area in RL with hypervascularity and capsule-irregularity, but the LL findings were normal with just a bit uneven capsule, which made us confused whether the PCa happened on the whole prostate in both

sides RL and LL or it just happen on the RL as RL has some typical findings of PCa.

• Elastography

1. NTE showed a very stiff area which was linked with hypoechoic area in 2D of RL. LL showed typically normal findings with a soft elastogram map and a well-defined border between TZ and PZ.

2. SWE showed abnormal stiffness measurements of RL, which mean stiffness value was 34kPa and max stiffness value was 115kPa.

3. While SWE showed normal stiffness measurements of LL, which mean stiffness value was 19kPa and max stiffness value was 36kPa.

Combined NTE and SWE results, we had more clinical evidence to confidently confirm that this patient had local PCa on RL, and LL of prostate seems to be normal.

Keynotes

1. Elastography tool has an accurate and consistent result of stiffness differences between LL and RL, high correlation with PCa diagnostic.

2. Combining NTE and SWE could help improve the characterization of prostate lesions and increase the detection of PCA.

healthcare within reach

MINDRAY SOCIAL MEDIA CHANNELS

LinkedIn



www.mindray.com

P/N: ENG-Ultrasound Journal-210285X5P-20220406

©2021 Shenzhen Mindray Bio-Medical Electronics Co.,Ltd. All rights reserved.

mindray
healthcare within reach