



## **Resona 7 Strain & Shear Wave Elastography in the Thyroid: Overview and Case Studies**

Pavlos S. Zoumpoulis MD, PhD  
Kendy C. C. Ng RDMS, RDCS, RVT, BSc, MBA

# Resona 7 Strain & Shear Wave Elastography in the Thyroid: Overview & Case Studies

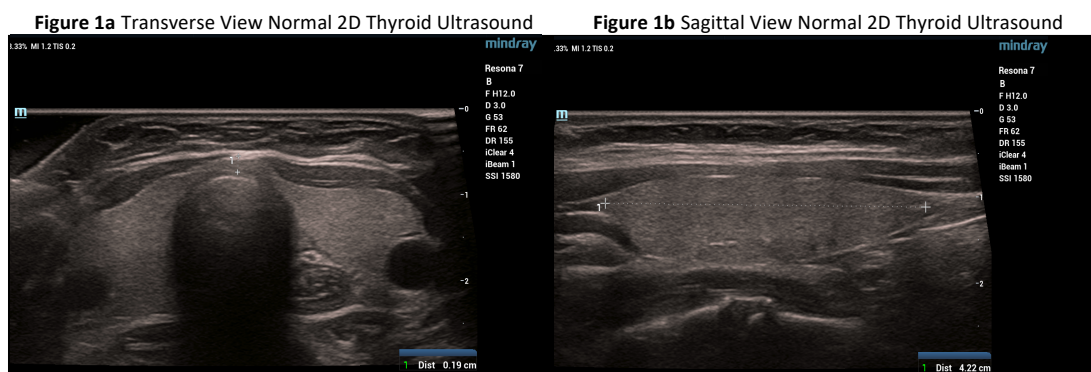
**Key Words:** SE (Strain Elastography), SWE (Shear Wave Elastography), STE (Natural Touch Elastography) STQ (ARFI Single Pulse Shear Wave Elastography), FNAC (Fine Needle Aspiration For Cytology), American Thyroid Association (ATA), American College of Radiology (ACR)

## 1. Background

Ultrasound is the modality of choice for the thyroid gland imaging. It is very sensitive in detecting and characterizing focal lesions, as well as in evaluating diffuse thyroid disease. Ultrasound, therefore, contributes in differentiating benign from malignant lesions (1) and provides effective patient management towards appropriate therapeutic decisions. Most thyroid nodules diagnosed are asymptomatic and benign, whereas about 5% are malignant. Moreover, thyroid nodules are most common in women of all races (1a). The containment of the thyroid cancer mortality greatly relies on improvements in early detection. Ultrasound and fine-needle aspiration biopsy (FNAB) are the modalities of choice for differentiating benign from malignant thyroid nodules. FNAB, however, has limitations, such as being invasive and time-intensive with potential complications. There is, therefore, a need for a non-invasive preoperative method that reduces the number of interventional procedures and unnecessary surgical procedures (1b).

## 2. Thyroid Echo Anatomy

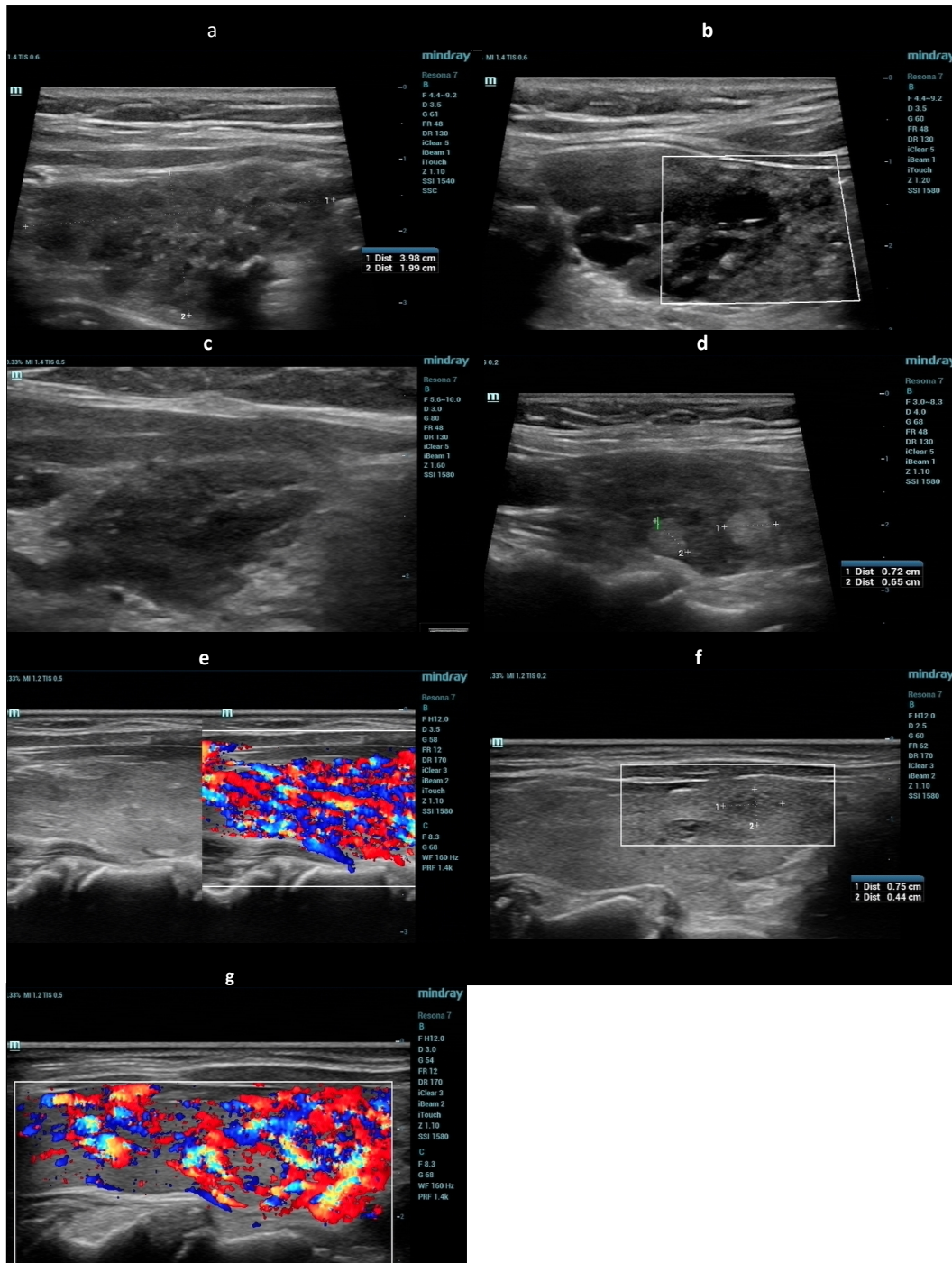
The normal thyroid gland consists of two lobes and a bridging parenchymal stripe called isthmus. It is, normally, located anteriorly and laterally on each side of the uppermost part of the trachea with each lobe between the trachea from one side and the carotid artery and jugular vein from the other. The upper esophagus is located posteriorly to the left lobe. Thyroid size varies, depending on age and body habitus. For adults, the normal range of measurements is 40-60 mm in longitudinal and 13-18 mm in anteroposterior diameters. The volume of the gland is calculated by measuring width, depth and length of each lobe with the formula  $V=W \times D \times L \times 0.523$ . Normal volume ranges are 10-15 ml for females and 12-18 ml for males. The echotexture of the normal thyroid parenchyma is homogeneously granulated. It is more echogenic than the surrounding muscles and of similar echogenicity to that of the parotid gland (1c).



## 3. 2D Ultrasound Thyroid Disease

### Diffuse Thyroid Diseases

This category includes a wide range of pathological entities. The most common is the Autoimmune Thyroid Disease, within which Hashimoto's Thyroiditis and Grave's Disease are the most common pathologies. The size of the gland, the B-mode echotexture and the vascularity in Color Doppler vary in autoimmune thyroid disease, depending on the course and stage of histological tissue modifications. The thyroid gland may, therefore, either be diffusely enlarged or of normal size, depending on the acute or chronic phase of the disease. The parenchyma may be heterogeneous with an overall coarse appearance, with reduced (focal or diffuse) echogenicity. Areas of increased echogenicity, micronodular (1-5mm) patterns with ill-defined margins and echogenic fibrotic septa may be present. The gland usually has irregular lobulated margins. At the late stages of Hashimoto's Thyroiditis, diminished size and atrophy are prominent. Color Doppler initially shows diffuse increased vascularity. In later stages of gland atrophy, vascularity may be poor or absent. In regard with Grave's disease, the so called "thyroid inferno" may be observed with color Doppler, due to excessive hypervascularity and arteriovenous shunting.



**Figure 2** US images of different patients with chronic thyroiditis: a-b) Hashimoto's Thyroiditis with heterogeneous micro-nodular echotexture. Larger confluent, hypoechoic nodules (not cysts) are also seen, mainly in b. c) Hashimoto's Thyroiditis. The gland has lobulated margins while echogenic fibrous septa are seen inside it. d) Hyperechoic benign nodules on the background of a chronic thyroiditis. e) Hashimoto's Thyroiditis. Excessive vascularity throughout the entire gland. f) Hypoechoic area with unclear margins. g) Grave's disease. Increased vascularity in the entire gland.

### Thyroid Cystic or Partially Cystic Nodule

Most cystic lesions result from degeneration of hyperplastic nodules and are usually benign. The echogenic colloid content in cystic lesions can be differentiated from solid tissue from its characteristic acoustic posterior enhancement of the US beam. 20% of the cystic lesions show marginal macro-calcifications. Echogenic foci with posterior comet-tail artifacts are commonly seen in the periphery of cystic or partially cystic nodules. They are a major benignity sign. These echogenic foci should be differentiated from microcalcifications (too small to induce posterior acoustic shadow and without posterior comet-tail artifact), that denote possibility of malignancy in a thyroid nodule.

### Thyroid Benign Focal Nodule

Benign nodules comprise of cystic or partially cystic nodules, multinodular goiter, hyperplastic adenomatous nodules and adenomas. Benign solid nodules appear iso- or hyperechoic in 2D US images. They have well-defined margins and a thin hypoechoic halo rim. Adenomatous nodules are hypoechoic lesions with well-defined margins and may show cystic degeneration.

### Thyroid Malignant Nodule

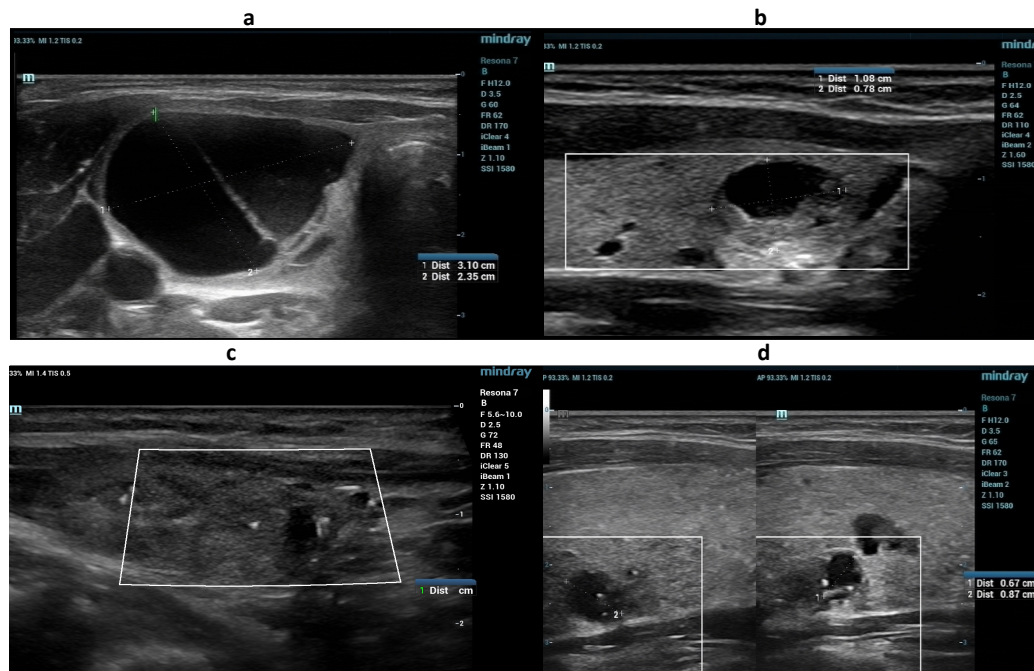
Malignant lesions include papillary carcinoma (most common form, 80% of thyroid carcinomas), Follicular carcinoma (5-15%), medullary carcinoma (5%), anaplastic carcinoma (2%), Lymphoma (4% - non-Hodgkin's type) and Metastases (1d).

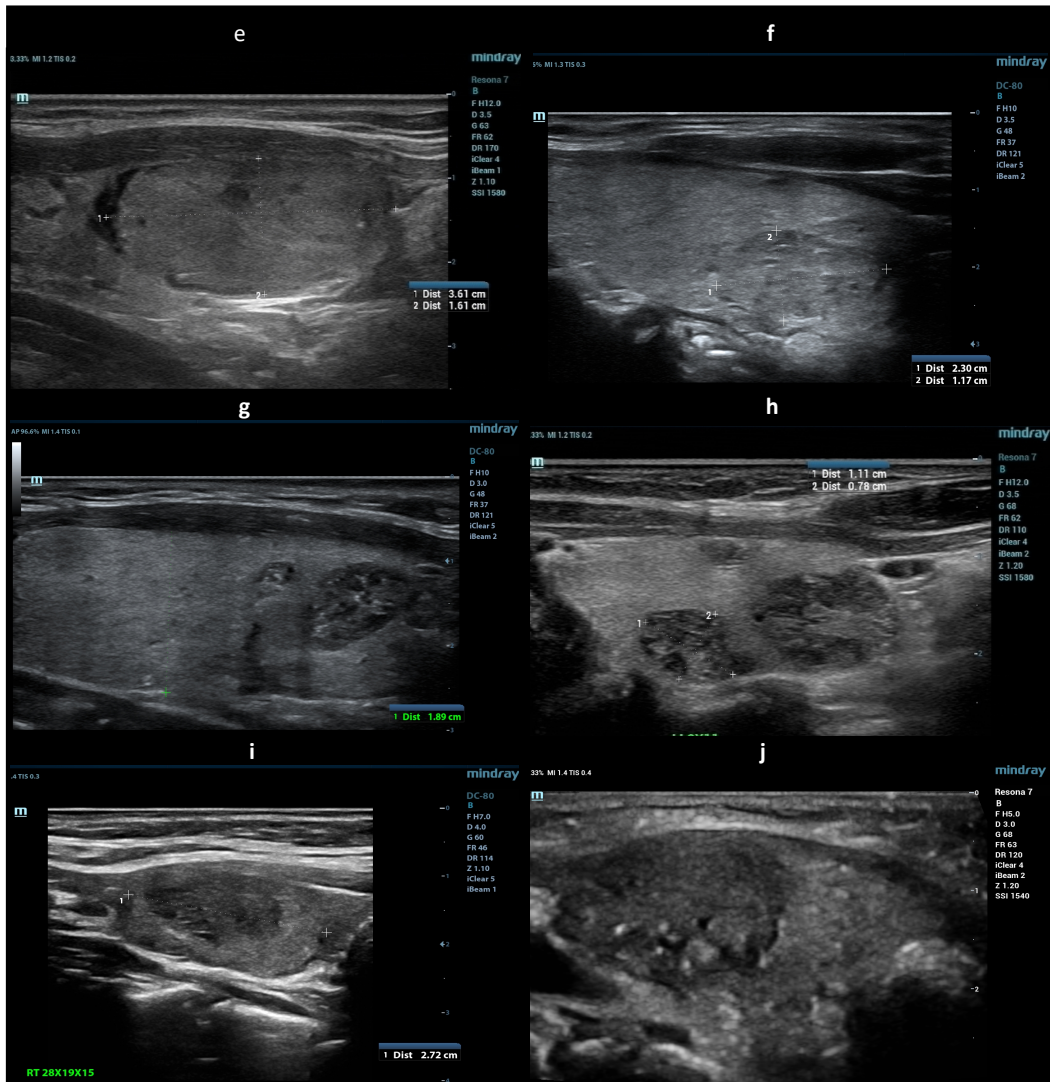
US appearance of papillary carcinoma shows marked hypo-echogenicity, with irregular shape and internal heterogeneity with microcalcifications or coarse calcifications. They are often taller than wide in shape. Metastatic cervical lymph nodes may be present. The follicular variant may be iso- or moderately hypo-echoic and often has a peripheral halo and a round or oval shape. Follicular carcinoma is similar to follicular adenoma in the US examination.

Medullary carcinomas appear as hypoechoic nodules with microcalcifications or coarser calcifications. Anaplastic carcinoma is a rare but very aggressive tumor, usually found in older female patients. It appears with marked hypo-echogenicity, diffuse involvement of the whole lobe, ill-defined borders, nodular metastases, extracapsular spread and vascular infiltration. Lymphoma appears as a markedly hypoechoic mass, sometimes with cystic necrosis. Lymphomas and metastases usually show non-specific appearance in conventional ultrasonography.

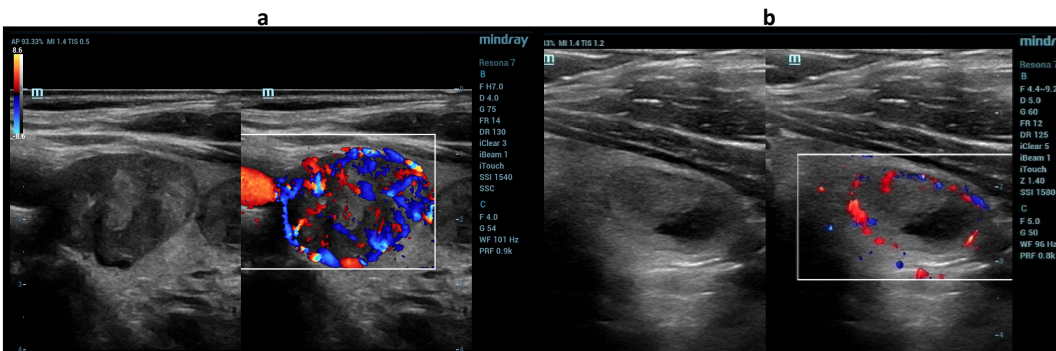
### Color Doppler study In Thyroid Nodule

Hypervascularity of solid nodules in color Doppler imaging usually represents functional autonomy of the nodule but is not always related with hyper-functioning of the gland. Thyroid cancers may show a hyperactive pattern of vascularity, although literature data remain controversial regarding the diagnostic usefulness of tumor vascularity. CEUS is an interesting research field for thyroid nodule characterization, mainly in cases that 2D ultrasound is challenging (2).





**Figure 3** US images of thyroid nodules of varying parenchymal composition (solid to cystic). a) Large cystic nodule. b) Mixed in echogenicity benign nodule with a solid and a larger cystic component. c) Mixed in echogenicity benign nodule with a large solid and a small cystic component. Microcalcification in the solid part without reverberation and a small echogenic foci displaying comet-tail artifact. Proved to be benign at FNAC. d) Small cysts with small echogenic foci displaying comet-tail artifact. e) Large isoechoic benign nodule with smooth margins, wider than taller. f) Isoechoic nodule with smooth margins, wider than taller, and with peripheral halo. g-h) Mixed in echogenicity different benign nodules with solid and micro- cystic component. i) Large solid nodule with a hypoechoic and an isoechoic component. j) Hypoechoic solid nodule with microcalcifications inside it and lobulated margins. FNAC of this lesion showed a papillary CA.



**Figure 4.** Role of color Doppler US. a) solid thyroid nodule with increased blood flow inside it at its margins. b) Mixed in echogenicity benign nodule with a solid and a cystic component. Blood flow is seen mainly at its periphery.

#### 4. TIRADS: Thyroid Nodule Differential Diagnosis Benign vs Malignant

Thyroid nodules are a common clinical condition with a prevalence of 2-6% at palpation; 19-35% at US and 8-65% at autopsy. B-Mode US is very sensitive in the detection of thyroid nodule but cannot reliably identify the few malignant from the common benign ones. Therefore, FNAC remains a final minimally invasive diagnostic method. US has been widely used to differentiate between malignant and benign nodules, based on a few features (solidity, marked hypo-echogenicity, irregular margins, micro-calcifications, taller than wide shape, interval growth of diameter >20%). There is variable reliability in studies for SE, SP, PPV and NPV of these features diagnosing malignancies. Since no single criterion is sufficiently sensitive and specific to evaluate malignancy, combinations of criteria should be used. In resemblance with the Breast Imaging Reporting and Data System (BIRADS), the Thyroid Imaging Reporting and Data System (TIRADS) was developed, a systematic approach to select thyroid lesions for FNA (3). Several versions of TIRADS have been in use by the major medical imaging Societies. They are, however, considered to be impractical and time consuming.

A more practical TIRADS was introduced by Kwak et al in 2011 (4), it contains 6 grades of thyroid focal disease classification.

##### TIRADS

- ❖ 1 Normal gland
- ❖ 2 Benign lesion
- ❖ 3 Probably benign
- ❖ 4 Suspicious for malignancy (4a one suspicious feature, 4b two features, 4c 3 or 4 features)
- ❖ 5 Probably malignant (All 5 suspicious features)
- ❖ 6 Biopsy proven malignancy

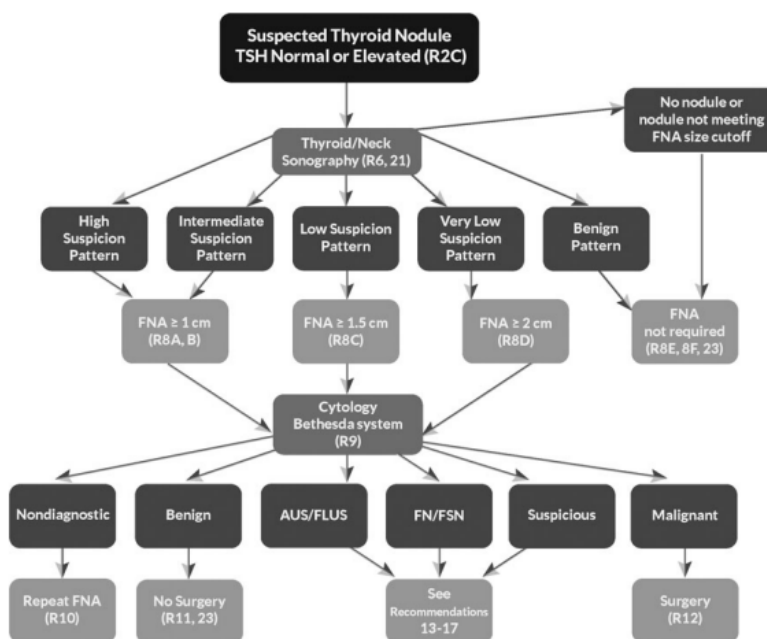
The suspicious ultrasound features of a nodule include solid component, marked hypogenicity, irregular or lobulated margins of the nodule, micro-calcifications and taller-than-wide shape.

TIRADS	Definition	Features	Fitted Probability of Malignancy
TIRADS 1	Normal thyroid parenchyma	-	-
TIRADS 2	Benign	-	0%
TIRADS 3	Probably benign	No suspicious feature	2-2.8%
TIRADS 4a	Low risk of malignancy	1 suspicious feature	3.6-12.7%
TIRADS 4b	Intermediate risk of malignancy	2 suspicious features	6.8-37.8%
TIRADS 4c	Moderate risk of malignancy	3-4 suspicious features	21-91%
TIRADS 5	High risk of malignancy	5 suspicious features	88.7-97.9%

Suspicious features: 1. Solid component. 2. Marked hypoechoogenicity. 3. Microlobulated or irregular margins. 4. micro-calcifications. 5. Taller-than-wide shape.

**Table 1** In 2015 the American Thyroid Society published updated guidelines on US assessment of thyroid nodules, which defined 5 risk categories with ascending malignancy rates, based only on US B-Mode criteria. Size of the nodule may also be used as an additional criterion. FNAC is not recommended for nodules < 1cm. FNAC is indicated if 2 or more risk criteria are present (3).

## ATA THYROID NODULE/DTC GUIDELINES

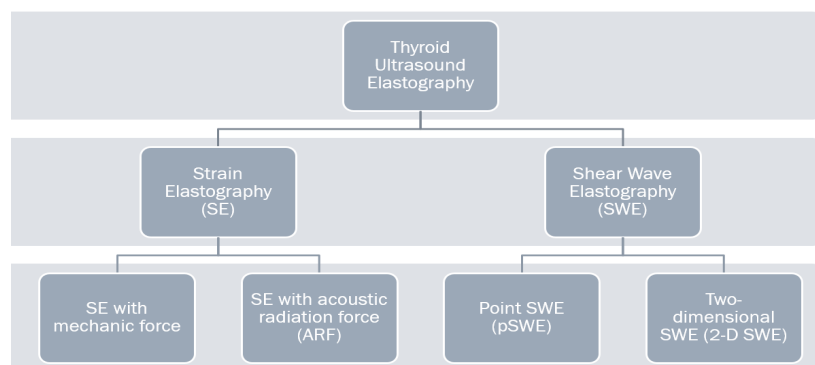


**Figure 5** Algorithm for evaluation and management of patients with thyroid nodules based on US pattern and FNA (5).

## 5. Elastography Application in Thyroid Nodules

Elastography is non-invasive, easily available, and can be included to the routine diagnostic study for the evaluation of thyroid nodules [6], adding stiffness information.

The thyroid gland because of its superficial position is rather easily evaluated with Elastography. Both Strain Elastography (SE) and Shear Wave Elastography (SWE) are based upon the assumption that thyroid malignancies are stiffer than benign lesions, and that the softer tissue is deforming easier than the harder nodule. The variants of thyroid Elastography techniques are presented in figure 6.



**Figure 6** Different variants of Thyroid Ultrasound Elastography, according to the excitation method and the way stiffness is expressed

Cut-off values vary in the literature. Cut-off values of strain ratios (SRs) for predicting malignancy are  $> 2-2.5$  for SE (range 1.5-5) (7). Most studies report cut-off values for differentiating benign vs malignant lesions ranging from 35 – 66 kPa for SWE. For benign nodules, the mean elasticity value is 15-28 kPa. There is a wide range of values and a single threshold cannot be established (range for malignant nodule 26.5-85 kPa from a recent meta-analysis) (7). Cut-off values variations in the literature are because of Inter- Intra-observer and inter-equipment variability. A recent (2019) multicenter study (8), evaluated SE and SWE in association with TIRADS-Kwak classification for the characterization of thyroid nodules. Their performance is presented in table 2.

	Sensitivity	Specificity	PPV	NPV	AUROC
TIRADS	59.6%	83.8%	50%	88.4%	0.717
SE	82.7%	92.7%	75.4%	95.2%	0.877
SWE	67.3%	82.7%	51.5%	90.3%	0.750

**Table 2** Elastography (either SE or SWE/STE) provides an additional information (stiffness) for the characterization of a thyroid nodule. Elastography shows equal or better performance than B-Mode TIRADS criteria for the characterization of a nodule. Such stiffness information of a thyroid nodule provided by SE & STE, in combination with its US features, aids in better selection of nodules referred to FNA and reduces unnecessary FNA of benign nodules (9). In ambiguous nodules, SE/STE may be useful in down grading or upgrading a suspicious lesion.

Even though many limitations exist, depending on the technology (Strain or Shear Wave) and scanning technique, they can be overcome by combining US and Elastography guided FNA with cytology examination. The main current guidelines for Elastography of the Thyroid Nodule come from ACR, EFSUMB, WFUMB and ATA. The ATA and the TIRADS do not consider stiffness as an indicator of malignancy (10). On the other hand, EFSUMB included elastography as a complimentary imaging tool for thyroid nodule screening and assessment (7).

## 6. Strain Elastography (SE)

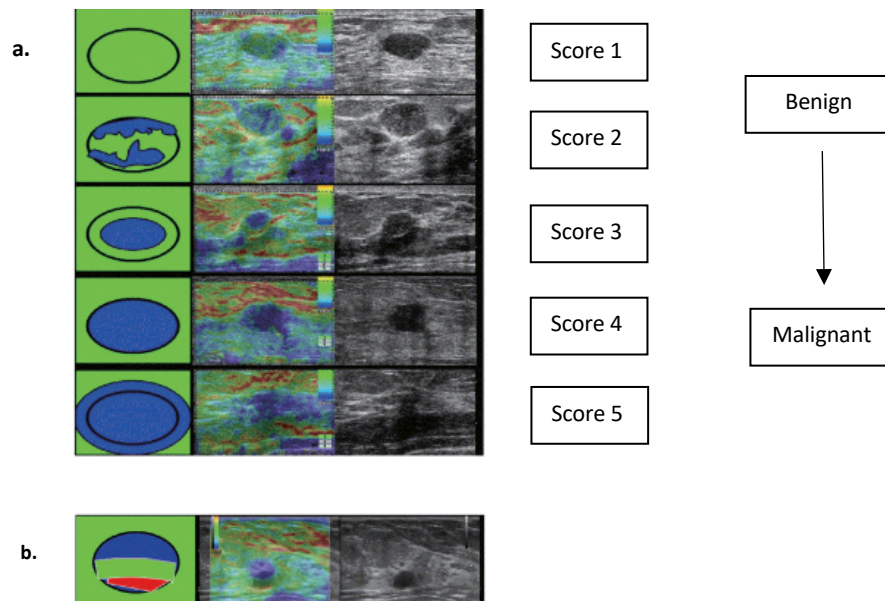
SE is a real-time non-invasive diagnostic technique that examines the stiffness and hardness of tissue. By Young's elasticity principle, the softer tissue can be deformed under external compression, easier than the harder ones. The deformability of the tissue is applied to differentiate malignant from benign lesions (11, 12).

The technique of SE was widely used in the examination of superficial tissues, including neck, prostate, breast, and thyroid, assessing their elasticity. When pathological conditions occur, both structure and elastic properties of tissue are affected.

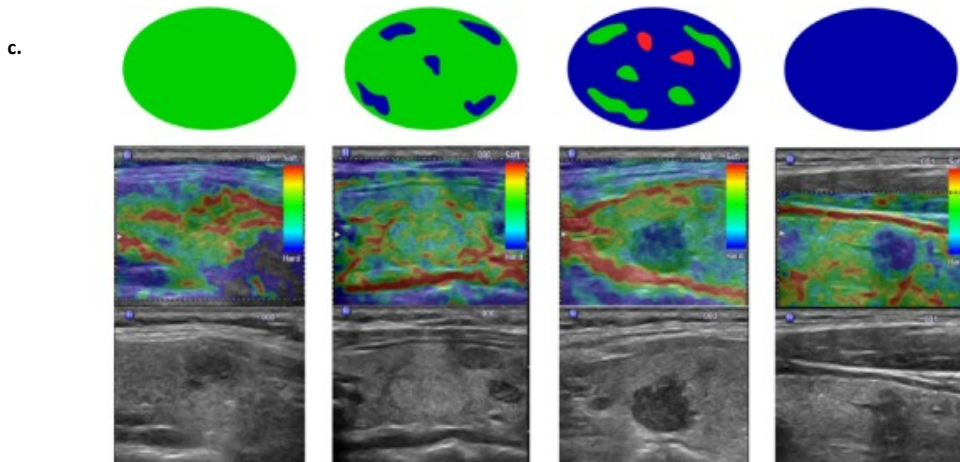
Strain elastography may be used either as a semi-quantitative method using several scoring systems with color maps of five, four or two patterns, or by calculating the strain ratio (SR), which compares the strain values of a focal thyroid lesion to those of the surrounding thyroid parenchyma or the surrounding muscles (Figure 7).

**Figure 7** SE Qualitative assessment Score for Strain Elastography.

- Strain elastography scores of 5 pattern scheme by Rago et al. (11). Score 1 indicates no difference in stiffness between the nodule and neighboring thyroid parenchyma. Score 2 indicates no difference of stiffness in a large part of the nodule. Score 3 indicates important difference of stiffness only at the peripheral part of the nodule. Score 4 indicates augmented stiffness an important part of the nodule. Score 5 indicates augmented stiffness in the entire nodule or in the area showing posterior shadowing.
- Typical SE feature of a cystic benign nodule (3 color line pattern).
- Strain Elastography SE 4 pattern scheme by Astoria et al. (12). Score 1 indicates elasticity in the entire examined area. A score of 2 indicates elasticity in a large part of the examined area. Score 3 indicates stiffness in a large part of the examined area. Score 4 indicates an entirely stiff nodule.

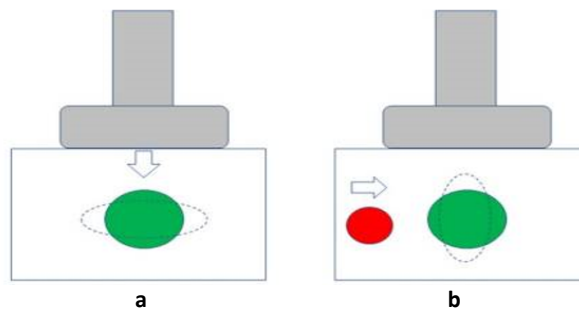






## 7. Strain Natural Touch Elastography (Resona 7 STE)

Natural Touch Strain Elastography (Mindray Resona 7) is an advanced imaging algorithm, automatically capturing natural cardiac pulsation through the carotid vessel. A natural compression effect is generated in the thyroid, creating a color map that indicates tissue stiffness of the thyroid and surrounding structures. Physicians only need to maintain good gel-skin acoustical contact during imaging, while no compression on the probe is necessary. Operators, therefore, do not have to focus on applying correct compression, assuring ease of use during scanning and providing better patient focus.



**Figure 8** The principle of different strain elastography techniques using different excitation methods.

- The elastographic image is acquired through tissue displacement caused by free-hand compression with a linear transducer.
- Natural Touch NTE strain image is generated through tissue displacement induced by compression caused by carotid artery and cardiac pulsations.

## 8. Shear Wave Elastography (Resona 7 SWE/STQ)

Real Time 2D Shear Wave Elastography in Mindray's Resona 7 is based on the deformation of a part of the tissue caused by a "push pulse". The US system generates shear waves which propagate in the tissue (perpendicularly to the axis of US beam) and estimates the velocity of Shear Wave propagation within the tissue. The SWE image is displayed alongside the gray-scale US image in real time. The US system then automatically calculates and displays the tissue stiffness in kPa by Young's modulus equation (Mean SWE value, min value, max value, standard deviation [SD]). User selectable ROIs (approximately 5-10 mm size) are placed manually in the stiffer part of the nodule and in the surrounding normal tissue to quantify tissue stiffness.

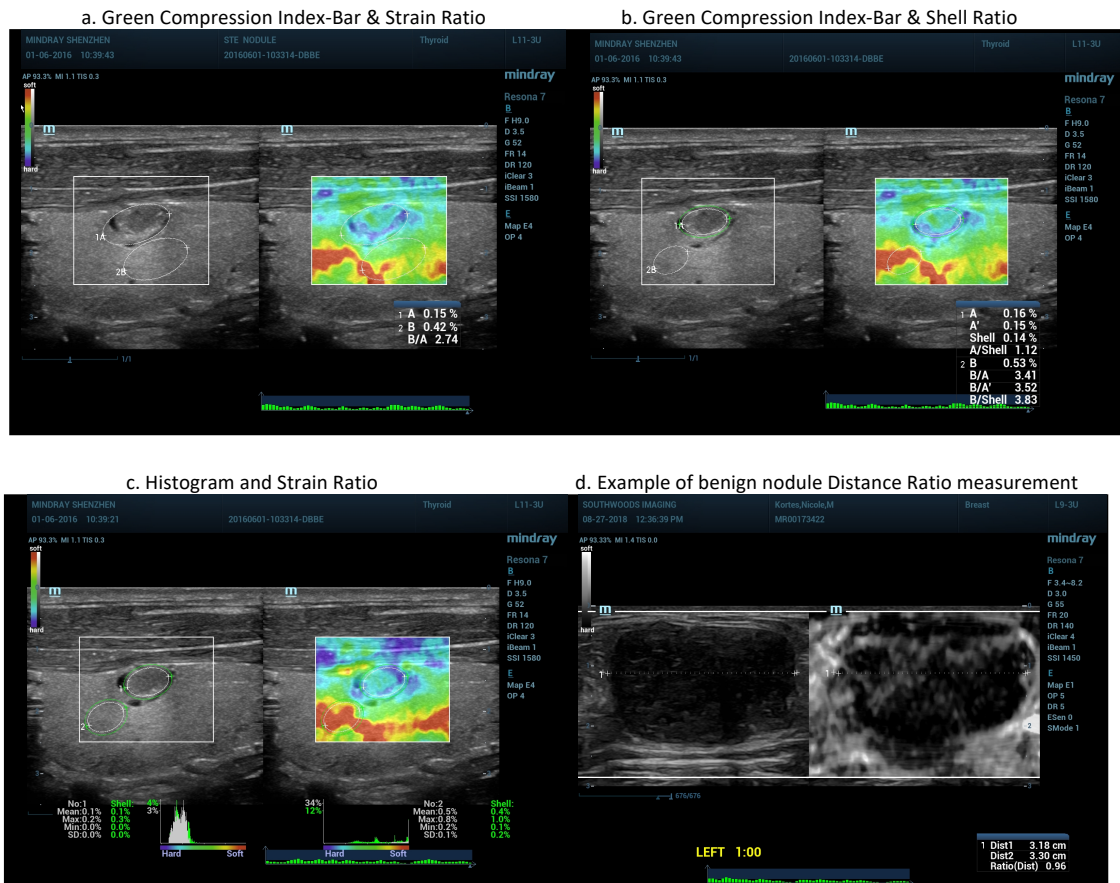
## 9. Strain Elastography (STE) Resona 7 Step by Step

**Patient/Probe Position:** The patient takes the supine position with the neck slightly extended. The patient must remain still without swallowing during the procedure. A linear probe (L14-5U, L11-3U or L9-3U Resona 7) is used depending on the availability and body habitus of the patient's neck. The transducer is placed perpendicularly to the thyroid in longitudinal scans. The operator maintains good probe-skin contact, while using adequate gel until a good 2D thyroid sagittal view image appears. If necessary, the user may apply proper manual or automatic image optimization (iScan) at an image depth of 3– 4 cm. A good quality 2D is the pre-requisite of an accurate Elastography study and measurement.

**Strain Elastography:** The operator presses the STE “soft Key” on the touch screen panel to activate SE and a 2D image simultaneously. A large elastogram ROI box should be used, including the nodule and surrounding healthy parenchyma. Patient is asked to cease swallowing and avoid deep breathing. Unnecessary excessive probe compression at this time will create artefacts and unreliable stiffness measurements. The operator then applies symmetrical probe/skin pressure and watches the green compression index bar at the bottom of the image. When proper probe/skin contact is maintained the index bar displays an even undulating wave form at the center portion of the index bar. Hard-suspicious nodules are displayed in red on the elastogram, soft nodules in blue and the intermediate nodules in hues of green. A 3-5 sec cine-loop is acquired for real time qualitative SRE evaluation and in order to select the best frames of SE images for measurement of the ratio between the nodule and the surrounding normal parenchyma stiffness value.

Semi-quantitative Strain Elastography assessment is carried out by comparing two ROIs: ROI 1 includes as much nodule area as possible (and only nodule area); ROI 2 placed in the adjacent parenchyma, includes an area with similar size and at a similar depth. After the ROIs are placed, the Resona 7 provides automatic calculation for the strain ratio (SR) by dividing the SRE value of the nodule with the one of normal parenchyma. At least two SR measurements from two different acquisitions per nodule are necessary.

**Figure 9** Main Resona 7 SE Semi-Quantitative Quantification parameters are a) Strain Ratio, b) Strain Shell, c) Strain Histogram. d) Strain Ratio by Distance



## 10. Real Time 2D Shear Wave Elastography (SWE/STQ Resona 7) Step by Step

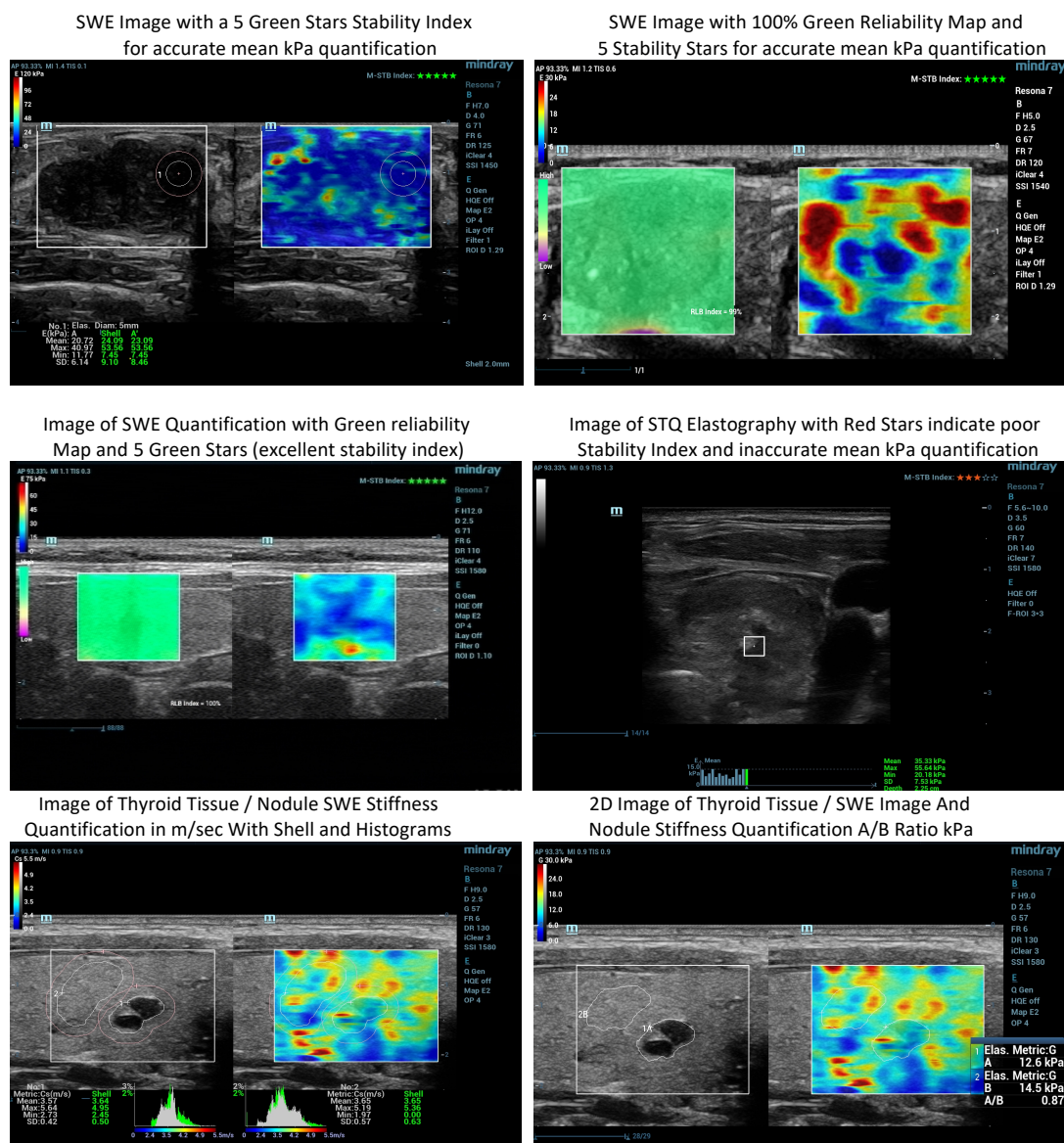
The operator places the transducer perpendicularly to the lesion without exceeding pressure. He/she then presses the STE “soft Key” on the touch screen panel to activate SWE/STE and a 2D image simultaneously. Red color artifacts (excessive probe compression) will create inaccurate stiffness measurements. A large Elastogram ROI box is applied, including the whole nodule and surrounding healthy parenchyma. The patient is asked to cease swallowing and avoid deep breaths. The color Elastography map differentiates normal tissue from stiffer nodules. A 3-5 sec cine-loop is acquired for real time qualitative SRE evaluation and to select the best frames of SWE images for measurement. The SWE Elastogram presents the tissue stiffness on a color scale map. In the default setting blue corresponds to soft tissue, red to hard tissue, and yellow to tissue of intermediate hardness.

The reliability index map (RLB map) and the 5-star stars stability index are helpful tools to indicate proper probe pressure on the skin and avoid motion artifacts. The operator uses the cine loop to select an image frame with green reliability index bar and green 5-star stability Index at the top right corner of the image. Any image frame with red color stars or less than 4 green stars index should be avoided for quantification means.

To perform an elasticity quantification on Resona 7, operators may use cine loop to select an image frame (preferably 5 green stars stability index) and place a 5 – 10 mm circular ROI on the hardest part (yellow or red) of the nodule on the SWE image. The Resona 7 then automatically calculates and displays the tissue stiffness in kPa or m/s by Young's modulus equation (Mean SWE value, min value, max value, SD). We can also obtain SR by comparing two ROIs: ROI 1 including the stiffest part of the nodule; ROI 2, of similar size, placed in the adjacent parenchyma at a similar depth. SRs obtained with STE are not comparable with SRs obtained with SE, even though they come from the same probe. Moreover, SRs in kPa are not comparable with SRs in m/s.

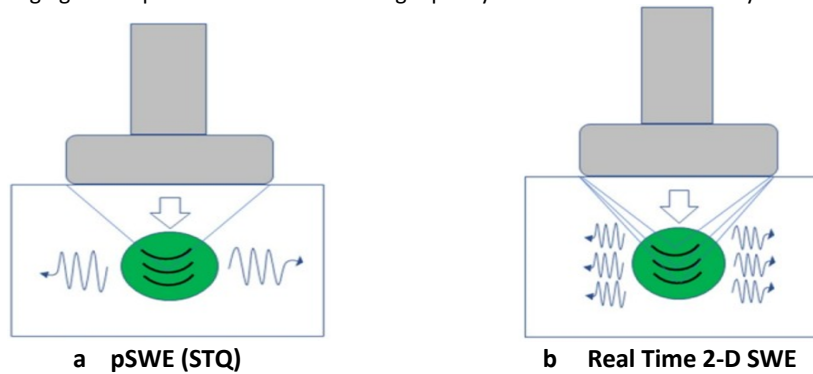
Resona 7 Shear Wave Elastography (SWE & STQ) Quantification parameters commonly used are i) Mean kPa, ii) kPa Ratio, iii) Shell Ratio kPa, iv) Histogram. The Reliability Map and the Stability Index assist users in obtaining accurate quantification data.

**Figure 10** Resona 7 main quantification parameters



Point SWE (STQ) single pulse quantitative method may be used alternatively to 2D real time SWE in order to achieve precise measurements in challenging anatomical patients and pathological conditions (i.e. patients with poor

breathing stability or with a significantly hard nodule) [Figure 11. a) STQ b) 2D SWE]. The positioning of the STQ box is challenging and depends on the B-Mode image quality criteria and the immobility of the tissue included.



**Figure 11** Principles of point Shear Wave Elastography (pSWE) and 2-dimensional Shear Wave Elastography (2-D SWE).  
a. pSWE uses acoustic radiation force (ARF) to mechanically excite the target tissue in a single focal location that creates a lateral shear wave.  
b. Real Time 2-D SWE uses ARF beams to generate shear waves in a full field of view

## 11. Strengths and Pitfalls of Thyroid Strain & Shear Wave Elastography

When performing Thyroid Elastography there are some bibliography validated pitfalls that may affect the reliable evaluation such as 1) Nodule features with calcifications and cystic changes; 2) Elastography performed on nodules with a calcified shell may generate weak shear wave; 3) Complex nodules with extensive cystic component are expected to alter nodule elasticity and may cause artifacts; 4) Malignant nodules could be missed by Elastography such as Follicular CA, which is rather soft and difficult to differentiate from benign nodules and some soft Papillary CAs; 5) SE is less useful in thyroid atrophy because diffuse fibrotic changes can cause parenchymal stiffening and reduce the SR of the nodule relative to the surrounding tissue. Using SWE is a better choice since it does not require a reference tissue (nodule stiffness is not altered by a background thyroiditis).

Also, superficially located or isthmic nodules are subjected to near-field artifact. Deeply located nodules can be affected by the attenuation or ARFI pulse decay phenomenon (14). Thyroid nodule size larger than 3 cm in diameter and, especially, its deeper portion are also subjected to artifacts (especially in SE – non uniform compression all over the nodule).

In the context of multinodular goiter and before performing FNAC, SWE/STE may show its usefulness by identifying “suspect” nodules. SWE/STE Elastography, in trained scanning hands and an ultrasound system providing good quality B-Mode image and SWE may add crucial stiffness information for characterizing a nodule as a FNAC candidate. Current guidelines recommend Elastography as a supplementary procedure for choosing nodules (especially in the cases of multinodular goiter) or position in nodules (hard areas) for FNAC. EFSUMB and WFSUMB guidelines indicate that SE and SWE are promising additional diagnostic tools in the differentiation of thyroid nodules and useful in the follow-up of negative for malignancy lesions (7).

Stiffness, however, is not the only characteristic of malignancy of any thyroid nodule since there are malignant thyroid tumors which are often softer than the normal thyroid parenchyma. Stiffness is not, therefore, always equivalent with nodular malignancy. The usefulness of Elastography in the Thyroid is not always of equivalent value as in other organs such as the liver and the breast where stiffness is one of the important decisive criteria for the differential diagnosis.

Combining SE and SWE techniques is helpful in downgrading and upgrading a suspicious TIRADS 4 to 3 and vice-versa and should be performed using a systematic approach with robust technique and validated departmental protocols. In these conditions the combination of SE and SWE can improve the sensitivity and specificity diagnosis for benign thyroid nodules and, therefore, limit the number of unnecessary FNAC and surgical procedures (15).

## 12. Inter-and-Intra-observer Bias & Scanning Variability

Several studies have investigated the reproducibility of Elastography in relation with the level of experience of the physicians as presented in Table 3. SWE often shows better reproducibility than SE. Manual external compression in SE leads to operator-dependent variability. Although SWE is less operator-dependent, external pressure can affect SW propagation through insulated tissue and operator error is the most common type source of artifacts in SWE. Thus, US Elastography should be performed by experienced operators using objective parameters and quality indicators (13).

Description	Intra-observer agreement										Inter-observer agreement
	Observer 1		Observer 2		Observer 3		Observer 4		Observer 5		
	Agreement (%)	k-value (SE)	Agreement (%)	k-value (SE)	Agreement (%)	k-value (SE)	Agreement (%)	k-value (SE)	Agreement (%)	k-value (SE)	
Composition	95.0	0.88 (0.12)	100.0	1.00 (0.00)	90.0	0.83 (0.11)	95.0	0.91 (0.09)	90.0	0.75 (0.17)	0.55 (0.04)
Echo-Pa	75.0	0.57 (0.16)	100.0	1.00 (0.00)	90.0	0.83 (0.11)	100.0	1.00 (0.00)	75.0	0.53 (0.17)	0.48 (0.04)
Echo-Pb	85.0	0.69 (0.16)	95.0	0.91 (0.09)	95.0	0.89 (0.11)	100.0	1.00 (0.00)	80.0	0.52 (0.21)	0.50 (0.05)
Echo-M	90.0	0.80 (0.14)	100.0	1.00 (0.00)	100.0	1.00 (0.00)	95.0	0.84 (0.16)	90.0	0.67 (0.18)	0.49 (0.04)
Margins	85.0	0.70 (0.16)	95.0	0.90 (0.10)	95.0	0.88 (0.12)	95.0	0.88 (0.12)	85.0	0.63 (0.20)	0.39 (0.05)
"Halo"	80.0	0.68 (0.13)	85.0	0.76 (0.12)	85.0	0.77 (0.12)	90.0	0.67 (0.19)	75.0	0.62 (0.14)	0.41 (0.04)
Capsule	80.0	0.64 (0.17)	95.0	0.91 (0.09)	85.0	0.72 (0.15)	80.0	0.59 (0.18)	75.0	0.50 (0.19)	0.40 (0.04)
Macro	100.0	1.00 (0.00)	95.0	0.83 (0.17)	95.0	0.64 (0.33)	100.0	1.00 (0.00)	95.0	0.64 (0.33)	0.61 (0.05)
Micro	95.0	0.89 (0.11)	95.0	0.90 (0.10)	90.0	0.77 (0.15)	90.0	0.78 (0.14)	90.0	0.74 (0.17)	0.57 (0.05)
Vascularity	90.0	0.86 (0.10)	90.0	0.74 (0.16)	100.0	1.00 (0.00)	95.0	0.85 (0.13)	95.0	0.87 (0.13)	0.34 (0.03)
Asteria Scale	78.9	0.71 (0.13)	78.9	0.70 (0.13)	94.7	0.92 (0.08)	73.7	0.61 (0.15)	73.7	0.65 (0.13)	0.33 (0.03)
Parenchyma	75.0	0.50 (0.19)	85.0	0.69 (0.16)	100.0	1.00 (0.00)	95.0	0.89 (0.10)	90.0	0.69 (0.20)	0.40 (0.05)
AT	95.0	0.88 (0.12)	80.0	0.47 (0.23)	95.0	*	95.0	0.64 (0.33)	100.0	1.00 (0.00)	0.25 (0.05)
Parenchyma vascularity	80.0	0.64 (0.16)	85.0	0.66 (0.17)	95.0	0.92 (0.08)	85.0	0.71 (0.15)	75.0	0.17 (0.26)	0.18 (0.04)
Average	86.0	0.74	91.4	0.82	93.6	0.86	92.0	0.81	84.9	0.64	0.42

\* The data structure did not allow k-value and SE to be calculated

**Table 3** Prospective analysis of inter-observer and intra-observer variability in multi ultrasound descriptor assessment of thyroid nodules (17)

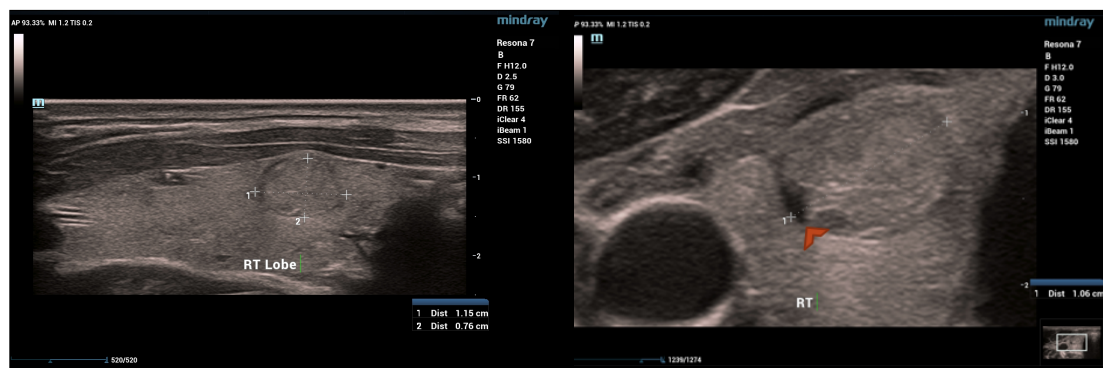
The Resona 7 system provides tools for more accurate Elastographic evaluation and for reducing inter-observer and intra-observer variation: The RLB Map and Green Stars Motion Stability Index for SWE and the Compression Index Bar for SE. Motion Artifacts caused by breathing and carotid motion can often generate compression and decompression movements and interfere with tissue. Longitudinal scans are preferable because they are less susceptible to effects and artifacts from the carotid artery.

### 13. Elastography For Guided Fine Needle Aspiration (FNAC) and Cytology

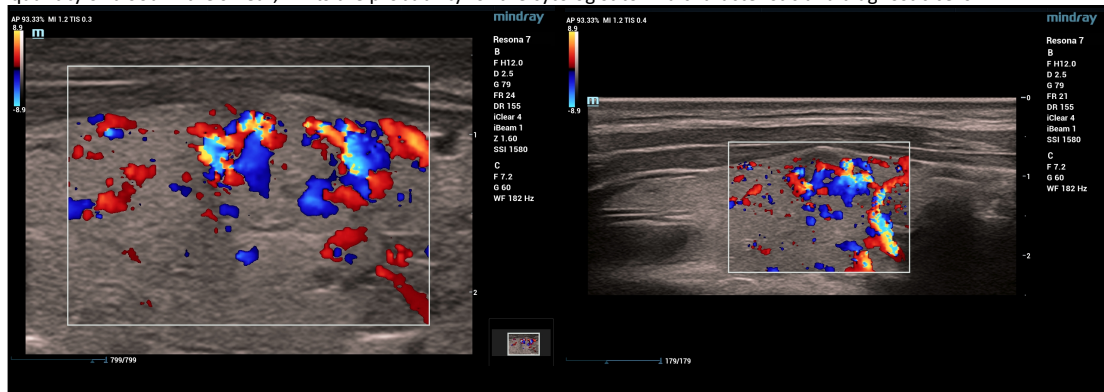
Although FNAC is considered the reference standard for the final differentiation between benign and malignant thyroid nodules, its reliability depends on the quality of the specimen and, therefore, from the US guidance of the tip of the needle. 2D, CD and SWE/STE performed in real-time before the placement of the needle are useful and complementary guiding tools. The placement of the needle is performed at the stiffest ROI under Elastography US guidance, in order to assure clear visualization of the tip of the needle. 3 - 5 different punctures, in different segments of the solid component of the nodule should be performed. The tip of the needle must be placed at different points inside the hypoechoic solid part. Once the edge of the needle is correctly positioned, back and front movements should be performed to achieve better probability of aspirating cells and, therefore, provide a representative specimen to the cytologist.

Before performing FNAC on a patient, the user may train himself using a phantom. Home-made phantoms made of jelly and containing cystic (digital part of elastic gloves) as well as solid "lesions" (pumice-less olives) are reliable training tools (16).

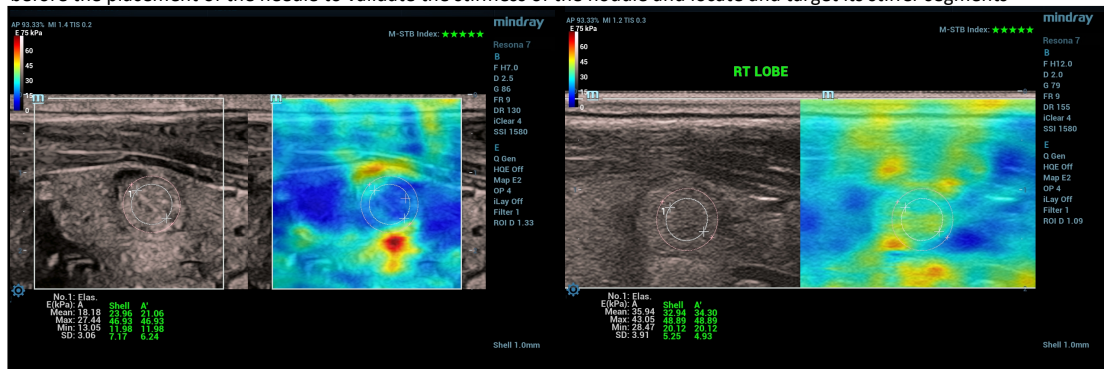
**Figure 12 & 13:** Isoechoic nodule with peripheric halo. Note the small hypoechoic nodule-in-nodule (arrow).



**Figure 14 & 15** Colour Doppler of the Isoechoic nodule. The nodule is hyper-vascular mainly in the periphery. The color Doppler exam visualizes the vasculature of the nodule. Visible vessels should not be included in the needle's trajectory since excessive quantity of blood in the smear, limits the probability for the cytologist to find characteristic and diagnostic cells



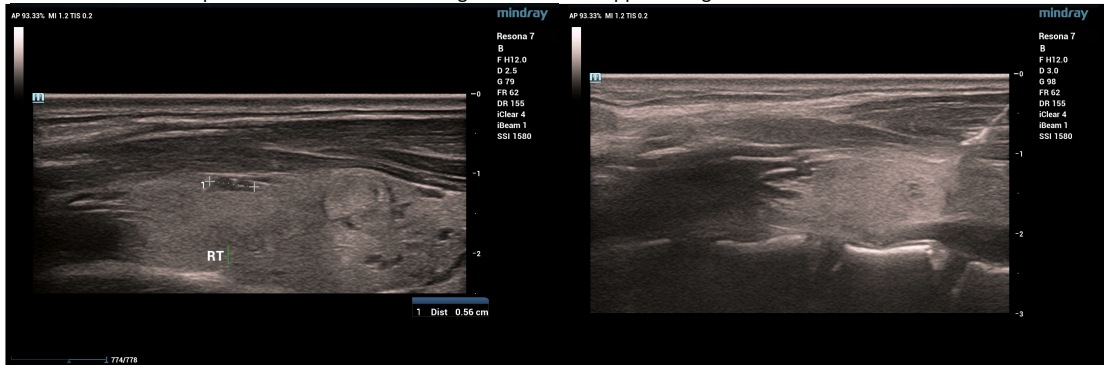
**Figure 16 & 17** STE of the nodule shows similar stiffness to the normal thyroid parenchyma. The elastography exam is performed before the placement of the needle to validate the stiffness of the nodule and locate and target its stiffer segments



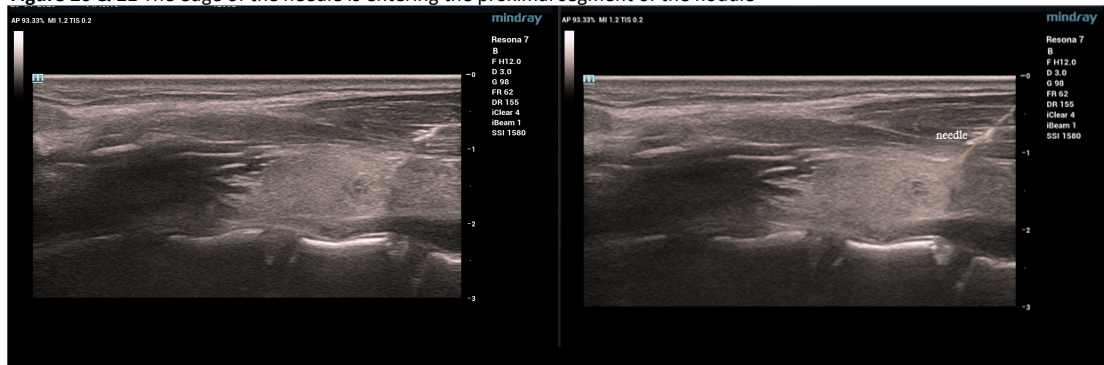
## 14. FNAC Technique

**Figure 18 & 19** Alignment of the probe. The US field contains the nodule in its maximum diameter.

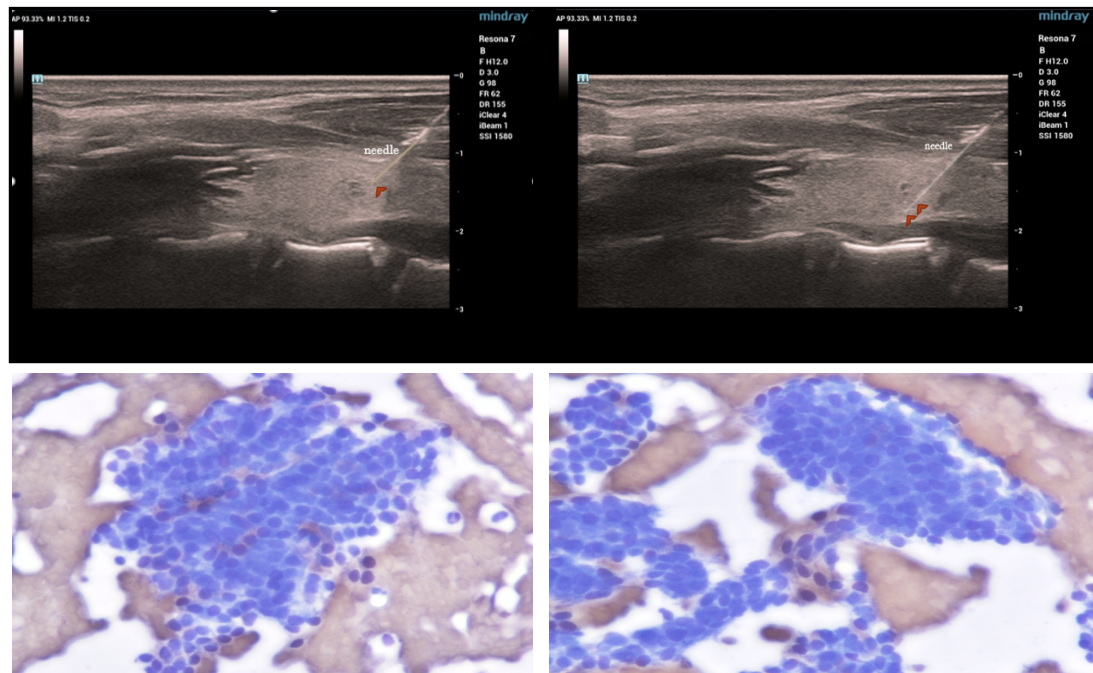
Alignment of the needle: Using the "free-hand" technique the needle is seen proximal to the probe in the subcutaneous tissue. Small movements are performed to visualize the edge of the needle approaching the nodule



**Figure 20 & 21** The edge of the needle is entering the proximal segment of the nodule



**Figure 23** The needle is trans-passing the nodule arriving at the distal segment (double red arrowhead) 3-4 back and through abrupt movements of the needle are performed between the proximal and the distal boarder of the nodule as mentioned above. The needle's movements are performed to "traumatize" the solid tissue of the nodule and assure the release of tiny tissue specimen and cells in front of the edge of the needle. No aspiration is needed. The vacuum effect inside the needle's cannula is enough for the specimen and the cells to enter the cannula.



Cytological Report: Many multi-cellular follicles with monolayer and homogeneous nuclei. Important quantity of colloid with many benign "naked" nuclei. The findings are typical for a benign hyperplastic nodule (**Bethesda II**)

## 15. Conclusion

Understanding the concepts of Strain and Shear Wave Elastography and 2D ultrasound imaging provided in this paper are vital for examiners to perform proper ultrasound thyroid evaluation. Operators need appropriate techniques on image optimization, cine acquisition, analysis and quantification to accurately measure stiffness.

A holistic ultrasound assessment of the Thyroid must always start with the cornerstones of good image quality of 2D-Mode, Color Doppler and Elastography in a multiparametric approach. 2D-Mode and the Color Doppler examination provide diagnostic details in differentiation of echo structure and hemodynamics of the nodule (Crucial US findings, helping in the classification of the nodule through the TIRADS system). SE and SWE in the hands of an experienced operator will provide excellent sensitivity and specificity of a suspicious thyroid nodule.

For both Strain and Shear Wave imaging, scanning technique and training are essential. Reliable results depend on the availability of specific software assuring ease of use and accuracy of measurements. The Resona 7 Reliability and Immobility Indexes are such useful tools that help in producing good quality Elastographic images and accurate measurements, as well as in reducing inter-and-intra-observer bias and scanning skill variations.

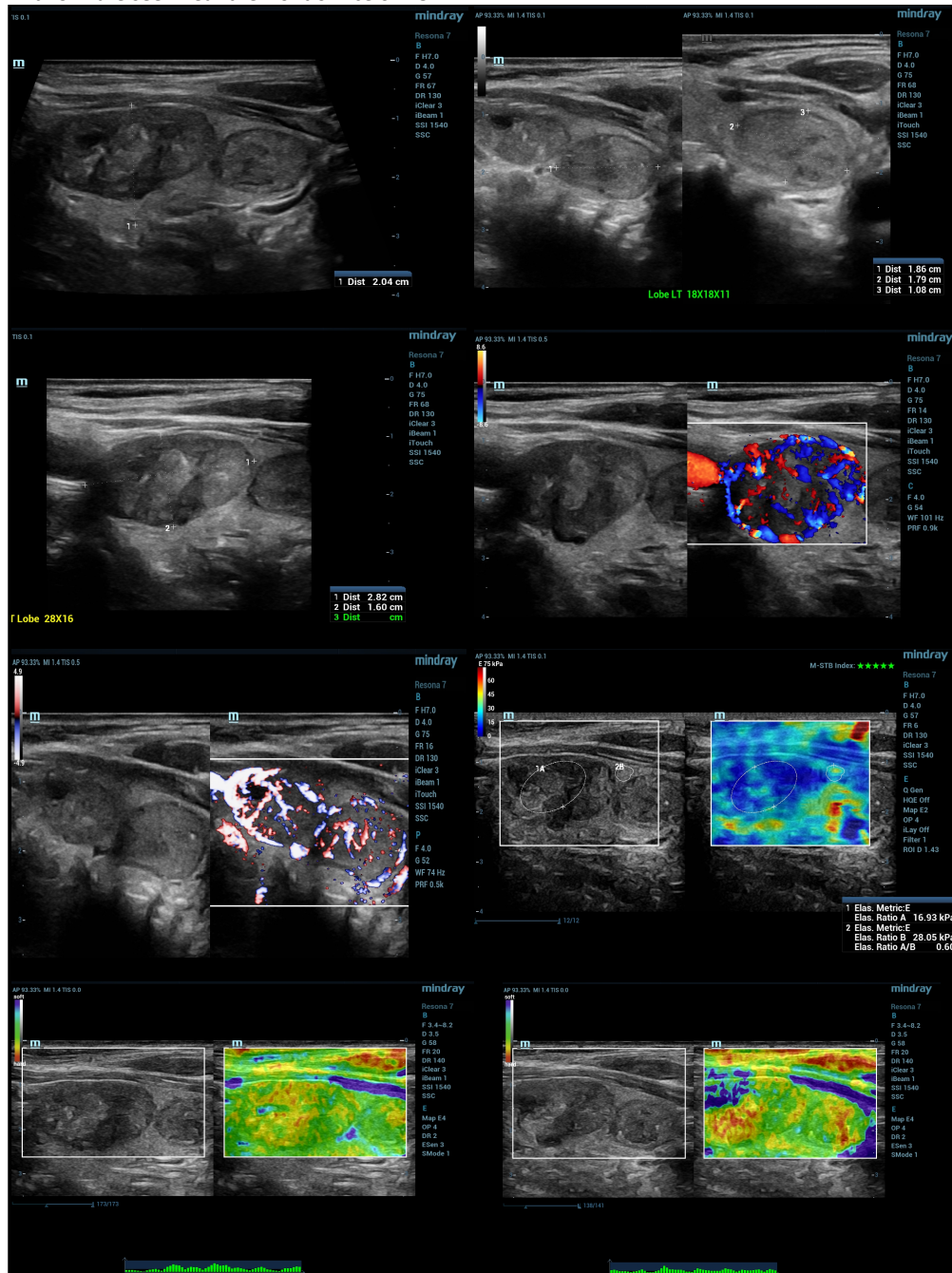
Strain and Shear Wave Elastography, used independently or jointly, can now be added to the routine 2D and Color Doppler examinations of the Thyroid. Strain and Shear Wave Elastography provide additional information for characterizing thyroid nodules, differentiating benign from malignant lesions. They improve the specificity and sensitivity enhancing patient management.

## CASE STUDY I: Multinodular Disease

- Female, 50 years old, annual follow-up examination, under thyroxine treatment, complains about mild difficulties in swallowing
- Biochemical markers: normal blood values of TSH, T3 & T4

### Ultrasound examination findings:

- Ultrasound/STE examination was performed for follow-up of known nodules
- Large solid nodules, mixed in echogenicity, well defined with clear margins, with peripheral halo and without calcifications inside them
- Color Doppler: increased vascularity inside and at the periphery of both nodules.
- STE/SWE & SRE: rather homogeneous soft color mapping inside the ROI. Stiffness values of both nodule with STE 15-17 kPa and 10 kPa for the small normal surrounding parenchyma. Some pressure artifacts with STE are seen near the front orifice of ROI



### Conclusion/practical comments:

For a reliable STE examination, a slight touch of the probe over the skin after applying enough amount of gel is suggested. With SRE, the estimation is done at the decompression cycle of the compression-decompression curve shown at the bottom of the image.

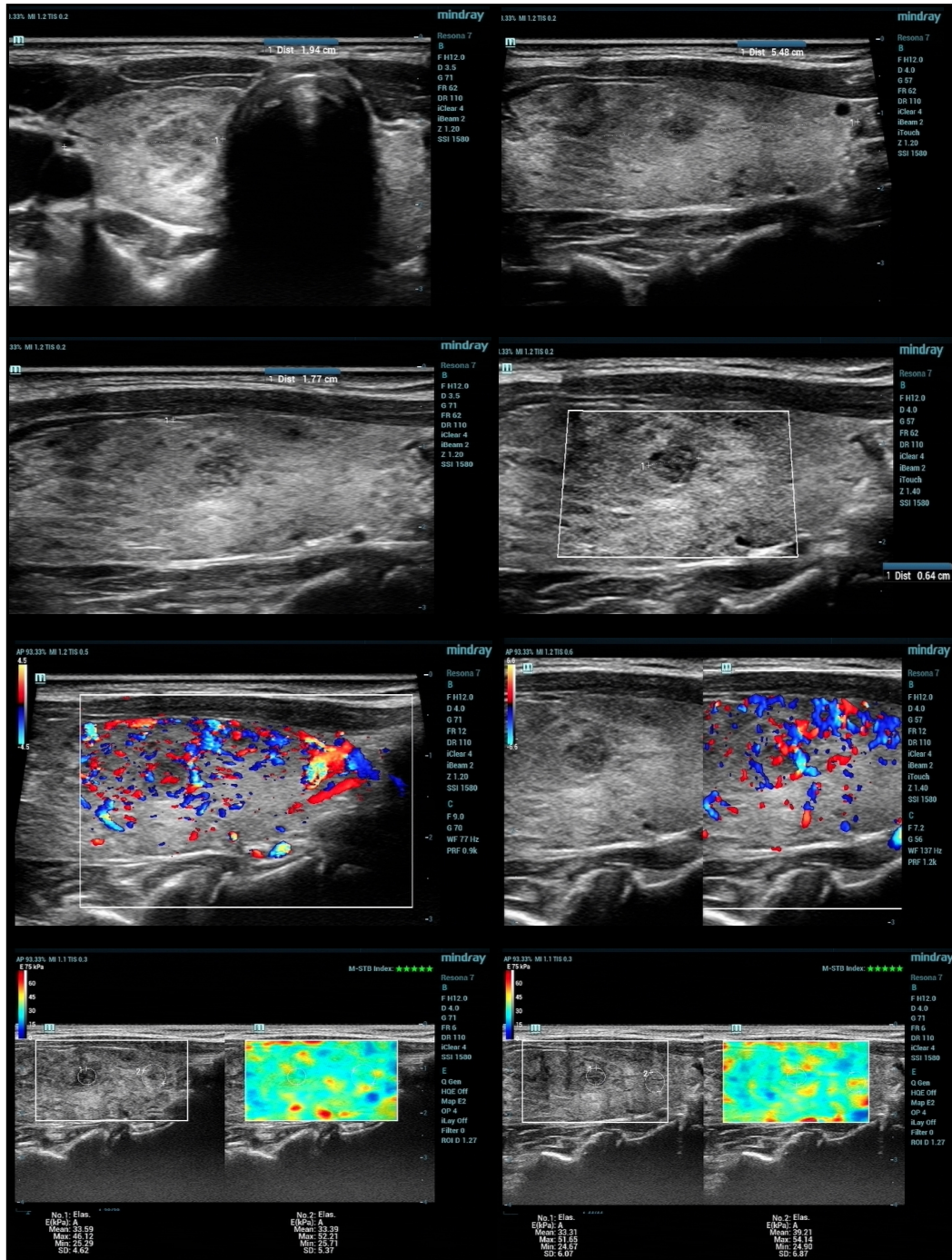


## CASE STUDY II: Chronic thyroiditis (Hashimoto)

- Female, 63 years old, with known Hashimoto disease, under thyroxine treatment.
- Biochemical markers: normal blood values of T3, T4 & TSH (due to treatment).

### Ultrasound/Elastographic findings

- US examination is performed annually to exclude malignancy on the background of chronic thyroiditis
- Heterogeneous echotexture with micronodular appearance, mild fibrosis, lobulated margins and a larger, solid, hypoechoic nodule
- Color Doppler study: increased vascularity of the thyroid and of the nodule (mainly at its periphery)
- STE/SWE study: the nodule appears uniformly soft at elastography with stiffness similar to the surrounding parenchyma (33 kPa).



### Conclusion/practical comments:

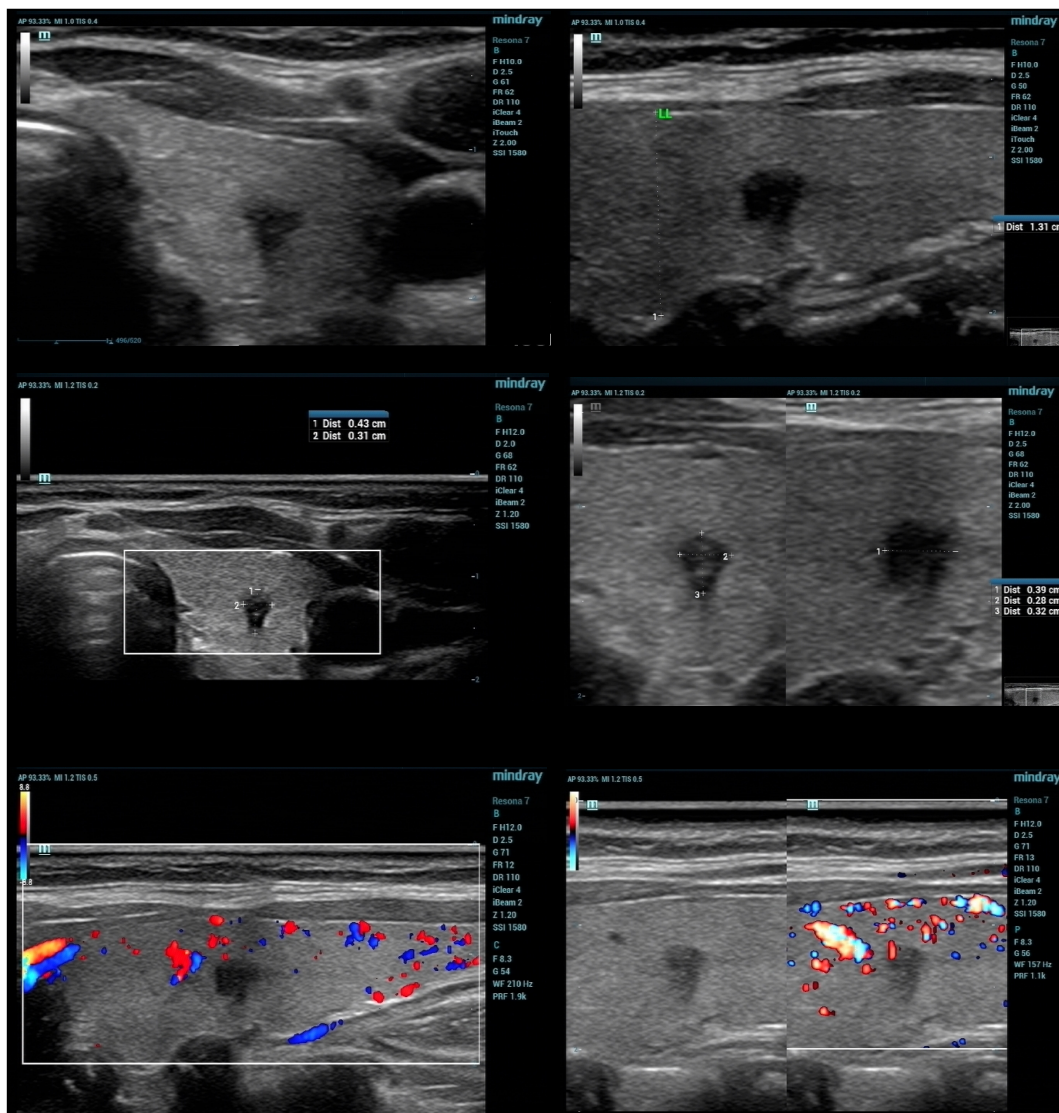
- Using elastography in this case we can avoid FNA of this nodule. During the long run of autoimmune chronic thyroiditis, hypoechoic pseudo-nodules may appear
- Every thyroid examination should be completed with the study of cervical lymph nodes, especially in segments II, III & IV.

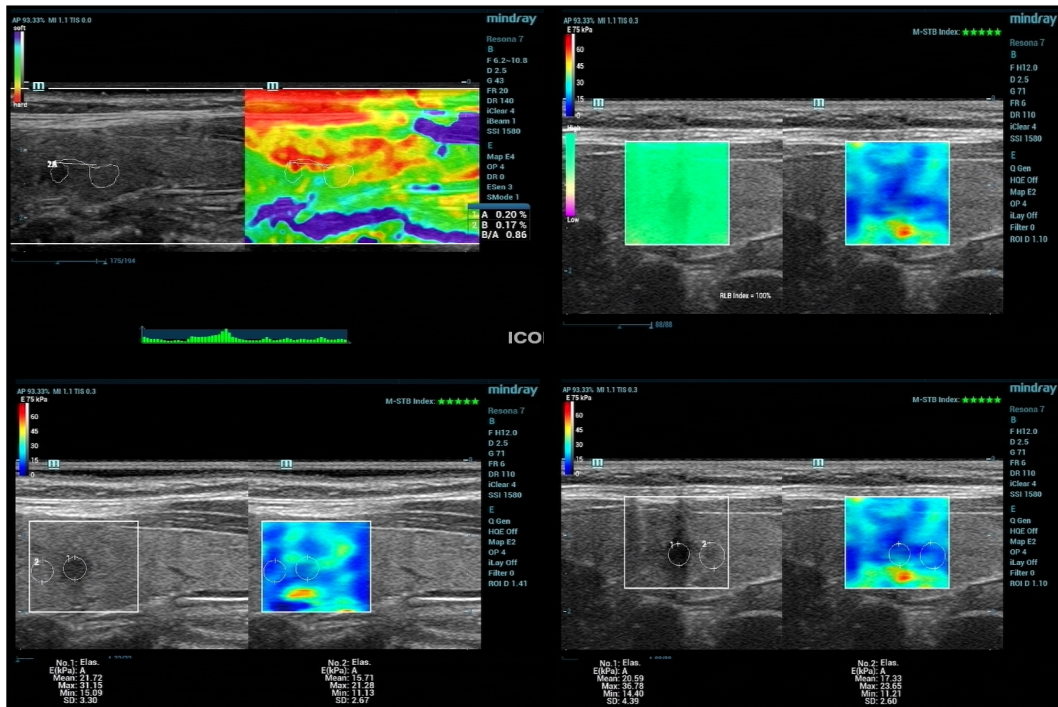
### CASE STUDY III: Papillary CA

- Male, 55 years old, first examination without known thyroid disease
- Biochemical markers: normal blood values of T3, T4 & TSH

### ULTRASOUND/ELASTOGRAPHIC Findings:

- Hypoechoic solid nodule, without peripheral halo, taller-than-wide, with a small calcification inside it and with rather irregular poorly defined margins (TIRADS 4c-3 suspicious features/moderate risk of malignancy)
- Color Doppler: no vascularity inside and at its periphery.
- STE/SWE & SRE: The nodule appears soft with both modalities, with stiffness slightly elevated in comparison to the surrounding parenchyma (21 versus 15 kPa – SR ~1)





**Conclusion/practical comments:**

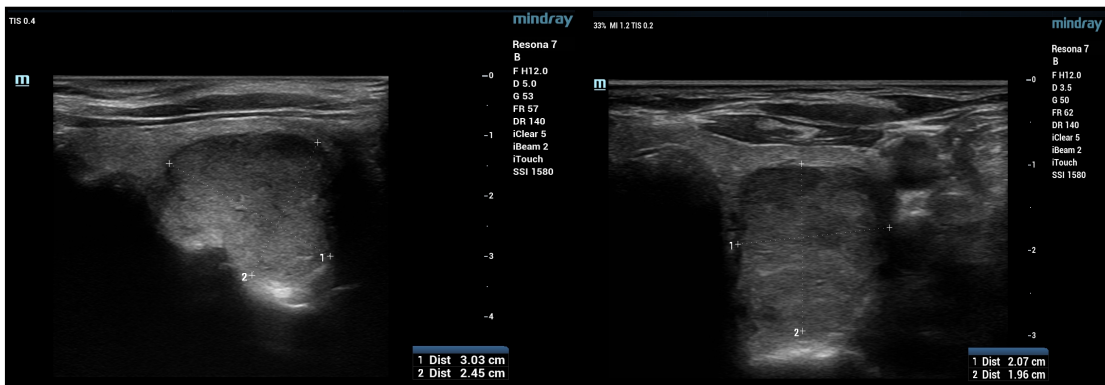
- The low stiffness of a nodule is not a contraindication for FNAC in case of existence of two or more suspicious ultrasound gray-scale characteristics. In thyroid pathology low stiffness alone is not a sufficient sign of benignity of a nodule.

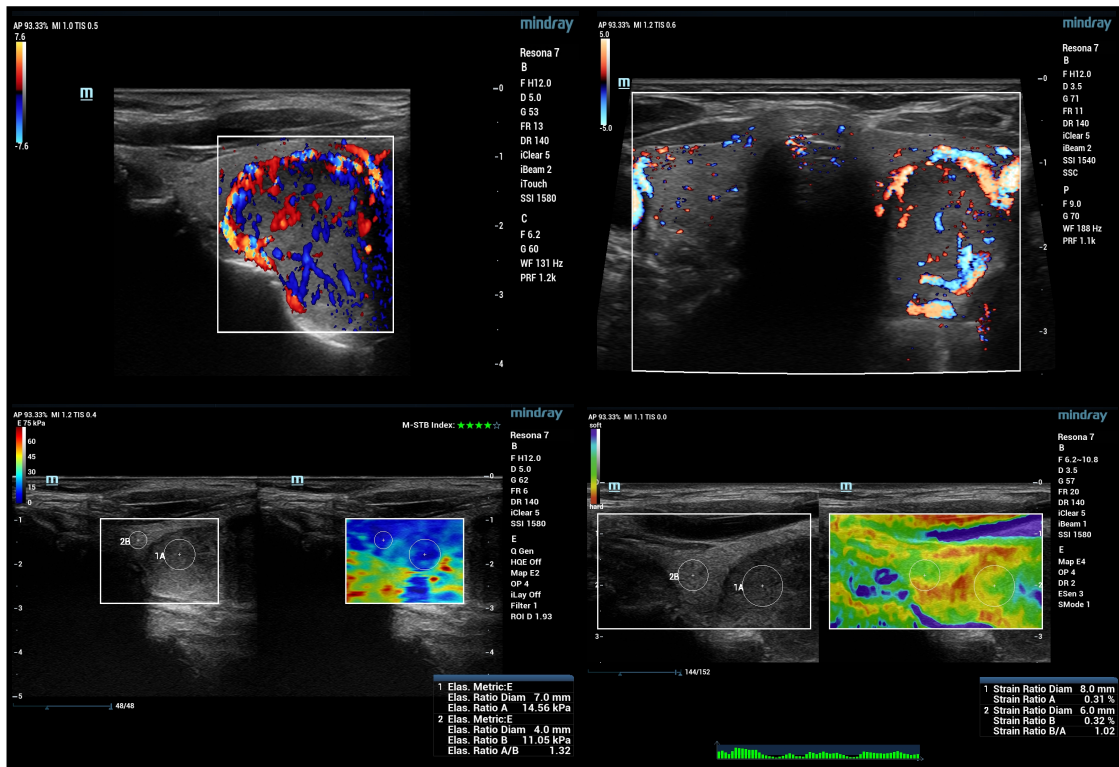
**CASE STUDY IV: single solid nodule**

- 62-year old woman, with known Thyroid Nodule, under treatment.
- Biochemical markers: normal blood values of T3, T4 & TSH.
- Asymptomatic patient, Follow-up exam.

**ULTRASOUND/ELASTOGRAPHIC Findings**

- Hypoechoic solid nodule, with peripheral halo, wider -than- taller, without micro- or macro-calcification inside it and with regular well-defined margins (TIRADS 3/4a mild hypogenicity of a part of the nodule - low risk of malignancy).
- Color Doppler: increased vascularity inside and at its periphery.
- STE/SWE & SRE: The nodule appears soft with both modalities, with stiffness slightly elevated in comparison to the surrounding parenchyma (15 versus 11 kPa – SR ~1-1.3).





### Conclusion/practical comments:

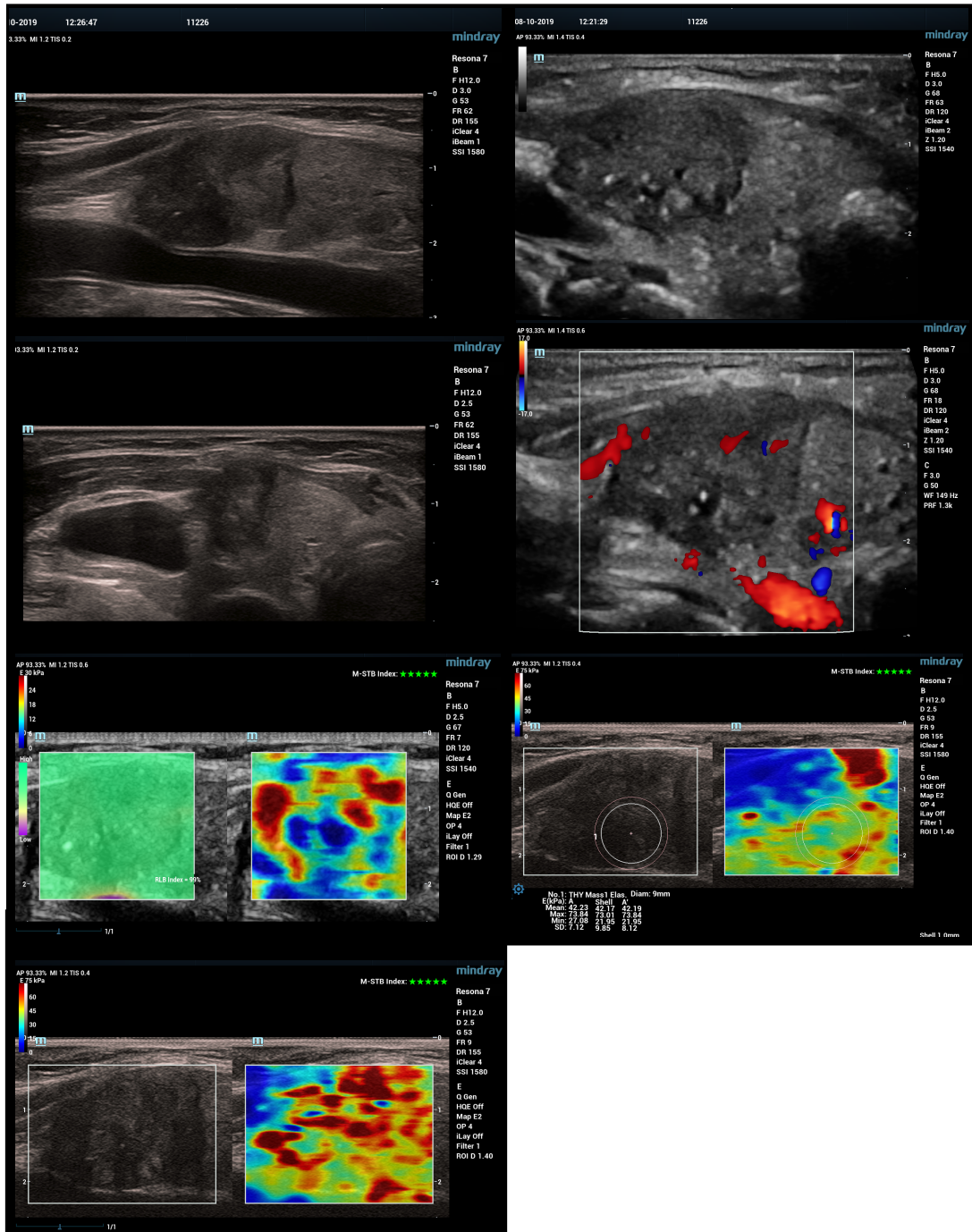
- Is FNA needed? Due to the gray-scale and elastographic findings of this nodule (low probability of malignancy 3.6-12% according to TIRADS system), there is no FNA need if there is no modification in the US appearance or the size of the nodule (increase over 20% from a previous examination).
- The presence of hypoechoic halo is a sufficient sign for benignity, even if the halo is not surrounding the entire nodule. The visualization of the halo depends on the orientation of the US beam.

### CASE STUDY V: Papillary CA

- 67-year old woman, with known Thyroid Nodule, under surveillance.
- Biochemical markers: normal blood values of T3, T4 & TSH.
- Asymptomatic patient, Follow-up exam.

### ULTRASOUND/ELASTOGRAPHIC Findings

- Hypoechoic solid nodule, with lobulated poorly defined margins, thin peripheral halo in some parts of the perimeter, wider-than-taller, with calcifications inside it (better seen with the lower frequency linear probe L9-3U versus L14-5WU) and with disruption of the thyroid capsule (TIRADS 4c/5, hypo-echogenicity of a part of the nodule, lobulated margins, calcifications inside it - high risk of malignancy).
- Color Doppler: Low vascularity mainly inside the nodule and not at its periphery.
- STE/SWE & SRE: The nodule appears stiff (mean stiffness 43 kPa, max. stiffness 74 kPa).



### Conclusion/practical comments:

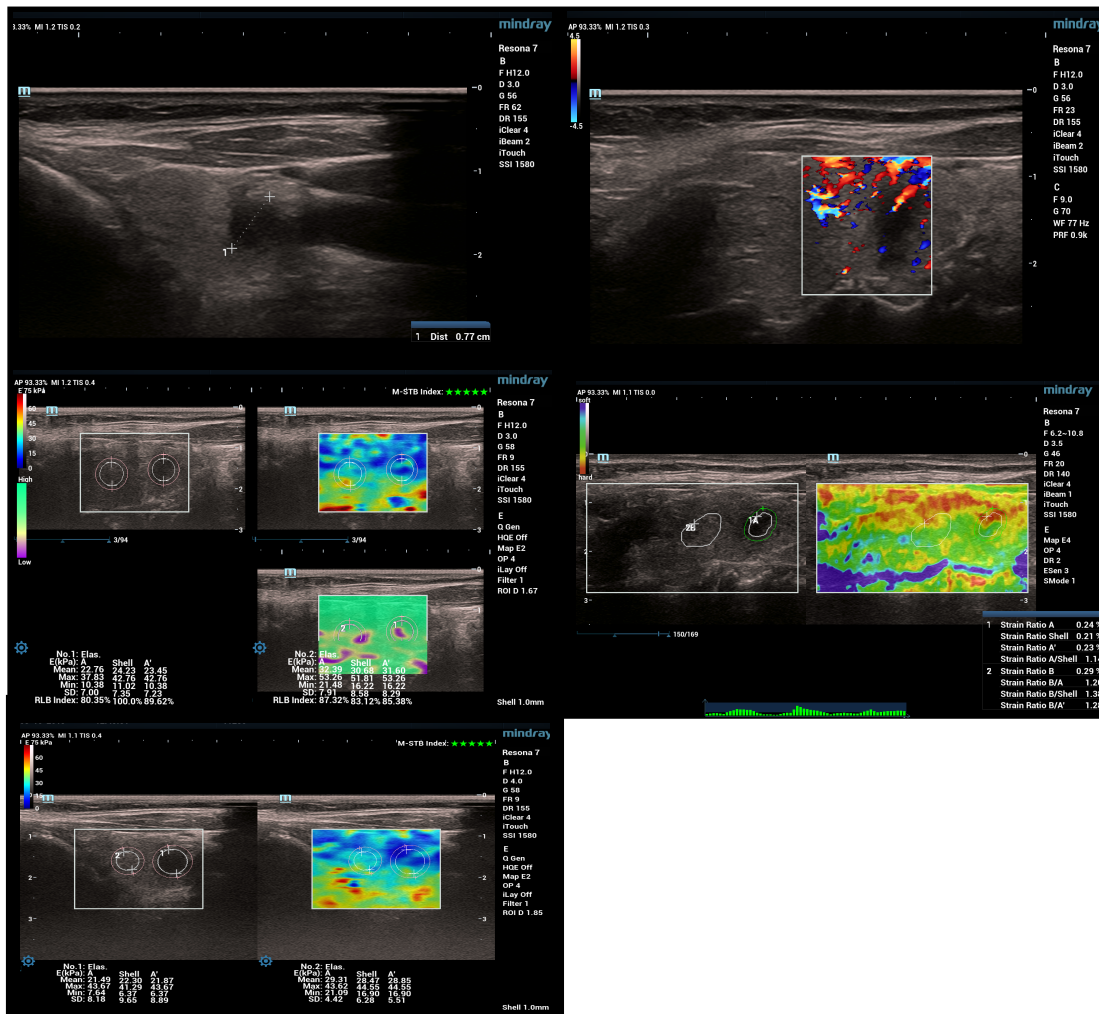
- Is FNA needed? Due to the grayscale and elastographic findings of this nodule (high probability of malignancy according to TIRADS system), there is a need for FNA in this patient. The operator should also search for suspicious cervical lymph nodes in the nearby area.

## CASE STUDY VI: Papillary CA

- 45-year Old man, with not proven Thyroid pathology. 1<sup>st</sup> examination.
- Biochemical markers: normal blood values of T3, T4 & TSH.
- Asymptomatic patient.

## ULTRASOUND/ELASTOGRAPHIC Findings

- Small hypoechoic solid nodule, with poorly defined margins, without peripheral halo, taller-than-wide, without calcifications inside it (TIRADS 4b, hypo-echogenicity of the nodule, lobulated poorly defined margins – intermediate risk of malignancy).
- Color Doppler: vascularity mainly inside the nodule and at a lesser degree at its periphery.
- STE/SWE & SRE: The nodule is not stiff with both modalities (mean stiffness of the nodule 22 kPa and max stiffness 41 kPa - nearly normal parenchyma 28 and 44 kPa – SR 1.3).



## Conclusion/practical comments:

- Is FNA needed? Low stiffness is not a contraindication for FNA in case of existence of two or more suspicious ultrasound gray-scale characteristics. The absence of hypo-echoic peripheral halo is a major sign of malignancy.
- Due to the grayscale and elastographic findings of this nodule (intermediate probability of malignancy according to TIRADS system), there is a need for FNA in this patient.

## Bibliography

- [1] American College of Radiology Practice Guideline 2017  
[http://www.acr.org/SecondaryMainMenuCategories/quality\\_safety/guidelines/us/us\\_thyroid\\_parathyroid.aspx](http://www.acr.org/SecondaryMainMenuCategories/quality_safety/guidelines/us/us_thyroid_parathyroid.aspx);
- [1a] Hegedus L. Clinical practice. The thyroid nodule. *N Engl J Med* 2004; 351:1764–71
- [1b] Kim JY, Lee CH, Kim SY, et al. Radiologic and pathologic findings of nonpalpable thyroid carcinomas detected by ultrasonography in a medical screening center. *J Ultrasound Med* 2008; 27:215–23.
- [1c] Normal ultrasound anatomy and common anatomical variants of the thyroid gland plus adjacent structures  
<https://doi.org/10.1016/j.clinimag.2019.07.002>
- [1d] Reading CC, Charboneau JW, Hay ID, et al. Sonography of thyroid nodules: a “classic pattern” diagnostic approach. *Ultrasound Q* 2005; 21:157–65
- [2] Sidhu S P, Cantisani V, Dietrich Ch, et al. The EFSUMB Guidelines and Recommendations for the Clinical Practice of Contrast-Enhanced Ultrasound (CEUS) in Non-Hepatic Applications: Update 2017. *Eur. Jour. of Ult* 2018. 39:154-180
- [3] Tessler FN, Middleton WD, Grant EG, Hoang JK, Berland LL, Teefey SA, et al. ACR thyroid imaging, reporting and data system (TI-RADS): white paper of the ACR TI-RADS committee. *J Am Coll Radiol.* (2017) 14:587–95. [10.1016/j.jacr.2017.01.046](https://doi.org/10.1016/j.jacr.2017.01.046)
- [4] Kwak JY, Han KH, Yoon JH et al. Thyroid imaging reporting and data system for US features of nodules: a step in establishing better stratification of cancer risk. *Radiology* 2011; 260:892-899
- [5] Haugen BR, Alexander EK, Bible KC et al. 2015 American Thyroid Association Management Guidelines for Adult Patients with Thyroid Nodules and Differentiated Thyroid Cancer: The American Thyroid Association Guidelines Task Force on Thyroid 2016; 26: 1-133.
- [6] Nightingale K, McAleavey S, Trahey G. Shear-wave generation using acoustic radiation force: in vivo and ex vivo results. *Ultrasound Med Biol* 2003; 29:1715–23.
- [7] Saftoiu A, Gilja O, Sidhu P et al. The EFSUMB Guidelines and Recommendations for the Clinical Practice of Elastography in non-Hepatic Applications: Update 2018. *Eur. Jour. of Ult* 2019. 40:425-453
- [8] Cantisani V, David E, Grazdhan H et al. Prospective Evaluation of Semiquantitative Strain Ratio and Quantitative 2D Ultrasound Shear Wave Elastography (SWE) in Association with TIRADS Classification for Thyroid Nodule Characterization Ultrasound of Thyroid Nodules. *Eur. Jour. of Ult* 2019. 39:488-511
- [9] Kagoya R, Monobe H, Tojima H. Utility of elastography for differential diagnosis of benign and malignant thyroid nodules. *Otolaryngol Head Neck Surg* 2010; 143:230–4.
- [10] Vorlander C, Wolff J, Saalabian S, et al. Real-time ultrasound elastography—a noninvasive diagnostic procedure for evaluating dominant thyroid nodules. *Langenbecks Arch Surg* 2010; 395:865–71
- [11] Rago T, Santini F, Scutari M et al. Elastography: new developments in ultrasound for predicting malignancy in thyroid nodules. *J Clin Endocrinol Metabol* 2007; 92:2917-2922
- [12]. Asteria C, Giovanardi A, Pizzocaro A, et al. US-elastography in the differential diagnosis of benign and malignant thyroid nodules. *Thyroid* 2008; 18:523-31.
- [13] Lim DJ, Luo S, Kim MH, et al. Interobserver agreement and intraobserver reproducibility in thyroid ultrasound elastography. *Am J Roenthenol* 2012; 198:896-901.
- [14] Comparison of Diagnostic Accuracy of Real Time Elastography/RTE & SWE in Differentiation Malignant from Benign Thyroid Nodules. Tian W et al. *Medicine* 2015; 94:e2312.
- [15] Azizi G, Keller J, Lewis M, et al. Performance of elastography for the evaluation of thyroid nodules: a prospective study. *Thyroid* 2013; 23:734–40.
- [16] Magri F, Chytiris S, Capelli V et al. Comparison of Elastographic Strain Index and Thyroid Fine-Needle Aspiration Cytology in 631 Thyroid Nodules. *Journal of Clinical Endocrinology & Metabolism* 2013; 98: 4790-4797
- [17] Dobruch-Sobczak K, Migda B, Krauze A et al. Prospective analysis of inter-observer and intra-observer variability in multi ultrasound descriptor assessment of thyroid nodules *J. Ultras.* 2019 Nov; 19(78): 198–206. Published online 2019 Sep 30. Doi: [10.15557/JoU.2019.0030](https://doi.org/10.15557/JoU.2019.0030)